IN THE SUPREME COURT OF THE STATE OF NEVADA

Case No.: 72737

Electronically Filed
Jul 25 2018 12:01 p.m.
Elizabeth A. Brown
Clerk of Supreme Court

LAURA DEMARANVILLE, surviving spouse of DANIEL DEMARANVILLE (DECEASED),

Appellant/Cross-Respondent,

v.

EMPLOYERS INSURANCE COMPANY OF NEVADA; and CANNON COCHRAN MANAGEMENT SERVICES, INC.,

Respondents,

and

CITY OF RENO,

Respondent/Cross-Appellant.

Appeal and Cross-Appeal From Order Granting In Part and Denying In Part Consolidated Petitions For Judicial Review

First Judicial District Court, Case No.: 15 0C 00092 1B

RESPONDENT/CROSS-APPELLANT CITY OF RENO'S SUPPLEMENTAL APPENDIX – VOLUME IV

McDONALD CARANO LLP
Timothy E. Rowe (NSBN 1000)
Chelsea Latino (NSBN 14227)
100 W. Liberty St., 10th Floor
Reno, Nevada 89501
Tel: (775) 788-2000
Fax: (775) 788-2020
trowe@mcdonaldcarano.com
clatino@mcdonaldcarano.com

Attorneys for Respondent/Cross-Appellant City of Reno and Respondent Cannon Cochran Management Services, Inc.

INDEX TO SUPPLEMENTAL APPENDIX
(Alphabetical)

DESCRIPTION OF DOCUMENT	VOLUME	PAGE(S)
Appeals Officer's Correspondence re: Index to Record on Appeal (dated 5/13/15)	I	SA 001-SA 006
Appeals Officer's Correspondence re: Index to Record on Appeal (dated 2/5/16)	I	SA 007-SA 009
Certification of Transmittal (filed 2/5/16)	I	SA 010-SA 012
Record on Appeal – Part 1 of 8	I	SA 013-SA 0100
Record on Appeal – Part 2 of 8	II	SA 101-SA 200
Record on Appeal – Part 3 of 8	III	SA 201-SA 300
Record on Appeal – Part 4 of 8	IV	SA 301-SA 400
Record on Appeal – Part 5 of 8	V	SA 401-SA 500
Record on Appeal – Part 6 of 8	VI	SA 501-SA 600
Record on Appeal – Part 7 of 8	VII	SA 601-SA 700
Record on Appeal – Part 8 of 8	VIII	SA 701-SA 786

CERTIFICATE OF SERVICE

I hereby certify that I am an employee of McDonald Carano LLP, and on the 25th day of July, 2018, a true and correct copy of the foregoing document was e-filed and e-served on all registered parties to the Supreme Court's electronic filing system as listed below:

Evan B. Beavers
Samantha L. Peiffer
Nevada Attorney for Injured Workers
1000 E. William Street, Suite 208
Carson City, Nevada 89701

Mark S. Sertic
Sertic Law, Ltd.
5975 Home Gardens Drive
Reno, NV 89502

/s/ Carole Davis

ACADIA MEDICAL GROUP

PROGRESS NOTES

Donald D. VanDyken, M.D.
Dulynn Hastings, M.D.
Katie Lydon, APN

Name: Daniel Demaranville Date: 11-20-08 Chart #: 134430

DOB: H: W: 205 T: P: 70 BP: 120/80 R: 18

HPI	
Location, quality, severity, duration, timing, context, modifying factors, associated signs and symptoms.	

ROS	WNL	See note
Const	☑	☐
Eyes	☐	☐
ENT/mouth	☐	☐
CV	☑	☐
Resp	☑	☐
GI	☑	☐
GU	☐	☑
Musc	☑	☐
Skin/breasts	☐	☐
Neuro	☐	☐
Psych	☐	☐
Endo	☐	☑
Hem/lymph	☐	☐
Allerg/immun	☐	☐

PFSH	No chng	See note
Past	☐	☑
Family	☐	☐
Social	☑	☐

Exam	WNL	See note
Const	☑	☐
Eyes	☐	☐
ENT/mouth	☐	☐
Neck	☑	☐
Resp	☑	☐
CV	☑	☐
Chest (breasts)	☐	☐
GI (abdomen)	☑	☐
Lymph	☑	☐
GU	☐	☐
Musc	☑	☐
Skin	☐	☐
Neuro	☐	☐
Psych	☑	☐

No ✓: no review/exam

CC: 7 day recheck here for 1 month F/U

HPI: Dyspnea w/ prev DOE
Sow Hadot - dx 1 month
Bronchitis
6.1 lbs
P.C & SOB, Dyspnea
Ankles
Hand tremors better,
o - overall NAD
Neck: JVD 2+ carotids
lungs CTA
Card NRR - S1 S2 S3
Abd + BMT
Edema
A: DJS 788.42
Microhematuria 599.7
Tob abuse 305.1
GERD 530.81
Erythema
BP
P - continued
stop smoking.
Exit
RTC today
RTC 1/09

MEDICATIONS
Zantac 150 mg
Tiazac
Hydrocodone
Flomax
Dulcolax
Diuretic
50 mg

Received
OCT 15 2012
CCMSI-Reno

Couns/coord>50% ☐ Total time: _____ min. Couns/coord time: _____ min.

119

Developed by the editors of FPM, Copyright © 1995, 1997 American Academy of Family Physicians. Physicians may photocopy for use in their own practices; all other rights reserved.
"Two Tried-and-True Tools for E/M Documentation." Backer LA. Family Practice Management. October 2003:5 http://aafp.org/fpm/20030900/51twot.html

AMG-081 REV 3/04

ACADIA MEDICAL GROUP
HISTORY AND PHYSICAL EXAMINATION

Name: DANIEL E. DEMARANVILE Date: 1-27-09

Considering what is normal for you:
Please read each line and circle **bolded** areas of difficulty or fill in ____

Review of systems:

- EENT: Have you had any problems with your: **eyes, ears, nose or throat?**
- Pulm: Have you had any problems with: **breathing, coughing or phlegm?** Do you ever: **cough up blood?**
- Cardio: Have you had any: **chest pains, palpitations (unusual heart beats), or difficulty breathing (with exercise or when lying down?)** Have you had any **calf pain** when you walk?
- GI: Have you had any problems with: **your stomach or digestion, nausea or vomiting, or with your bowels such as: diarrhea, constipation, hemorrhoids or blood in your stool?**
- ~~If you are over~~ 50, when was your last flexible sigmoidoscopy or colonoscopy? 1 YR AGO
- GU: Are you having any problems with **urination?**
  - Men: do you have trouble starting your stream or emptying your bladder fully?
  - Women: do you **leak urine** when you cough, sneeze, laugh or strain?
- GYN: (for women only): Do you do monthly **breast self-exams?** Found any lumps?
  - Are you having any problems with your **menstrual period?**
  - When was your last **normal menstrual period?** ____
  - What do you use for **Contraception?** ____
- For both sexes: Do you have any sexual problems or concerns? Y (N)
  - Do you need any information about sexually transmitted diseases? Y (N)
- Musculoskeletal: Do you have any problems with your: **muscles, bones, or joints?**
- Exercise: How much **aerobic exercise** do you get each week? 0
- Neuro: Do you have any **unusual headaches?** Do you have any: **numbness, weakness tingling, seizures, passing out, or vision changes?**
- Endo: Do you have: a feeling that you are **warmer (or colder)** than most other people?
  - Do you feel unusually **tired?**
  - Do you have any problems with your: **skin, hair, or nails?**
- Sleep: Do you have any problems **sleeping?**
- Psych: Do you have any problems with feeling **depressed, "blue", anxious or panicked?**
  - Do you feel: **helpless, hopeless, or suicidal?**
  - Do you have problems with: **concentrating** or with **having fun?**

- UPDATES: (for the physician to do): (check if done)
- Past medical and past surgical history:
- Social history:
- Family history:

deceased note Held

Received
OCT 15 2012
CCMSI-Reno

©2003 Donald D. VanDyken, M.D.

Lance Ventura
Chart # 134430
Age 74 DOB 10/4/34

Physical Exam Form

Date 1/27/09 BP 110/68 Pulse 70/min Resp: 18/min Wt: 203 lbs Ht: 70 1/2 Shoe: Meds:

General/Head and Neck	WD ☐ WNL A &OX4 ☐ In NAD ☐
Head/ Scalp nl ☐	Eyes PERRL ☐ Fundi nl ☐ EOMI ☐
Ears - TM nl ☐ Canals nl ☐	Nose- nl ☐
Mouth/Teeth nl ☐	Pharynx nl ☐
Neck Thyroid nl ☐ Nodes nl ☐	Carotids No Bruits ☐ Pulses nl ☐
Chest	
Lungs CTAP ☐ No R/W/C ☐	Breasts/Nipples nl ☐ No Masses d/c ☐ Symm ☐
Heart RRR ☐ No M/R/G ☐	Axillary Nodes nl ☐
Ribs nl ☐	Chest Wall nl ☐ No CVAT ☐ No Spine TTP ☐
Abdomen	
Bowel Sounds nl ☐ No Masses ☐ Non-Tender ☐	
No Abd/Renal Bruits ☐	
LKKS nl ☐	
Male	
Scrotum nl ☐	Testes nl ☐
Penis nl ☐ Circumcised ☐	Prostate- nl ☐
No Hernias ☐	Ano-rectal nl ☐ } Hold
Female	
Vulva nl ☐	Vagina nl ☐
Cervix nl ☐ No CMT ☐ Pap Done ☐	Uterus nl Size ☐ Ante Straight Retro Smooth No Masses ☐
Adenexa nl ☐ N.T. ☐ No Masses ☐	No Cysatcele/ Rectocele ☐
Ano-Rectal nl ☐	STD (GC Chl RPR HIV Hep) Done ☐
Skin	
Moles nl ☐	No Abnl Lesions ☐ SKN
Extremities	
Pulses nl: Radial ☐ P.T. ☐ D.P. ☐ 2+	No Edema ☐
Cyanosis None ☐	Clubbing None ☐
Joints nl ☐ Full ROM ☐	Back nl ☐
Neuro	
Motor/Strength nl ☐	Reflexes: Cerebellar nl ☐ DTRs nl ☐
Sensation nl ☐ A&Ox4 ☐	Gait nl ☐
Cranial Nerves II-XII Grossly Intact ☐	

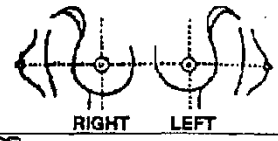

Assessment:		Plan:
1) GERD 530.81	PFT ☐	
2) DJS 788.69	CBC ☐	
3) Urgency incontinence 599.70	CMP ☐	1) Zantac 150 q PM 100/3
4) ED 302.72	Lipids ☐	2) Flomax 4 q D "
5) Trigger finger	UA ☐	3)
6) Dysphagia	PSA ☐	4) Viagra 50 q D 10/3
7) COPD	Hypothyrd ☐	5)
8)	Arth Panel ☐	6) Cialis 10 mg q D "
9)	LFTs ☐	7)
10)	Hep. Panel ☐	8) stop
11)	Hemclt X3 ☐	9)
12)	Mammo ☐	10) Eucrisa
13)	Dexa ☐	11)
14)	Echo ☐	12)
15)	EKG ☐	13)
	ETT ☐	14)
	Thallium ☐	15)

Received OCT 15 2012 CCMSP Reno

AMG 50 (10/03)

291 261 121

SA 303

ACADIA MEDICAL GROUP
RENO NEVADA

EasyOne(TM) DIAGNOSTIC 2.14
(c) ndd 2000-2005
SN 94581 RacNo 1393
27.01.09 16:54

Patient Information

Name	DANIEL DEMARANVILLE
ID	134430
Age	74
Height	5 ft 11 in
Weight	203 lbs, BMI 28.4
Gender	MALE
Ethnic	CAUCASIAN
Smoker	YES
Asthma	NO

Test Information

Test Date/Time	27.01.09 16:53
Post Time	--:--
Test Mode	DIAGNOSTIC
Interpretation	NLHEP
Predicted Ref	Knudson76
Value Select	BEST VALUE
Tech ID	KB
Automated QC	ON
BTPS (IN/EX)	-.--/ 1.02

Test Results

Your FEV1 is 50% Predicted. Your Lung Age is 132

Parameter	Baseline Best	Trial3	Trial2	Trial1	Pred	%Pred
FVC(L)	3.19	3.19	2.96*	2.66*	4.09	78
FEV1(L)	1.59*	1.58*	1.45*	1.59*	3.16	50
FEV1/FVC	0.50*	0.49*	0.49*	0.60*	0.78	64
PEF(L/s)	5.57*	5.57*	5.21*	5.44*	8.34	67
FEF25-75(L/s)	0.50*	0.50*	0.49*	0.79*	3.94	13
FET(s)	10.09	10.09	8.04	6.80	-.--	--

* Indicates Below LLN or Significant Post Change

Baseline Interpretation: FEV1 Var=0.02L 1.1%; FVC Var=0.24L 7.4%; Moderate Obstruction

Session Quality C

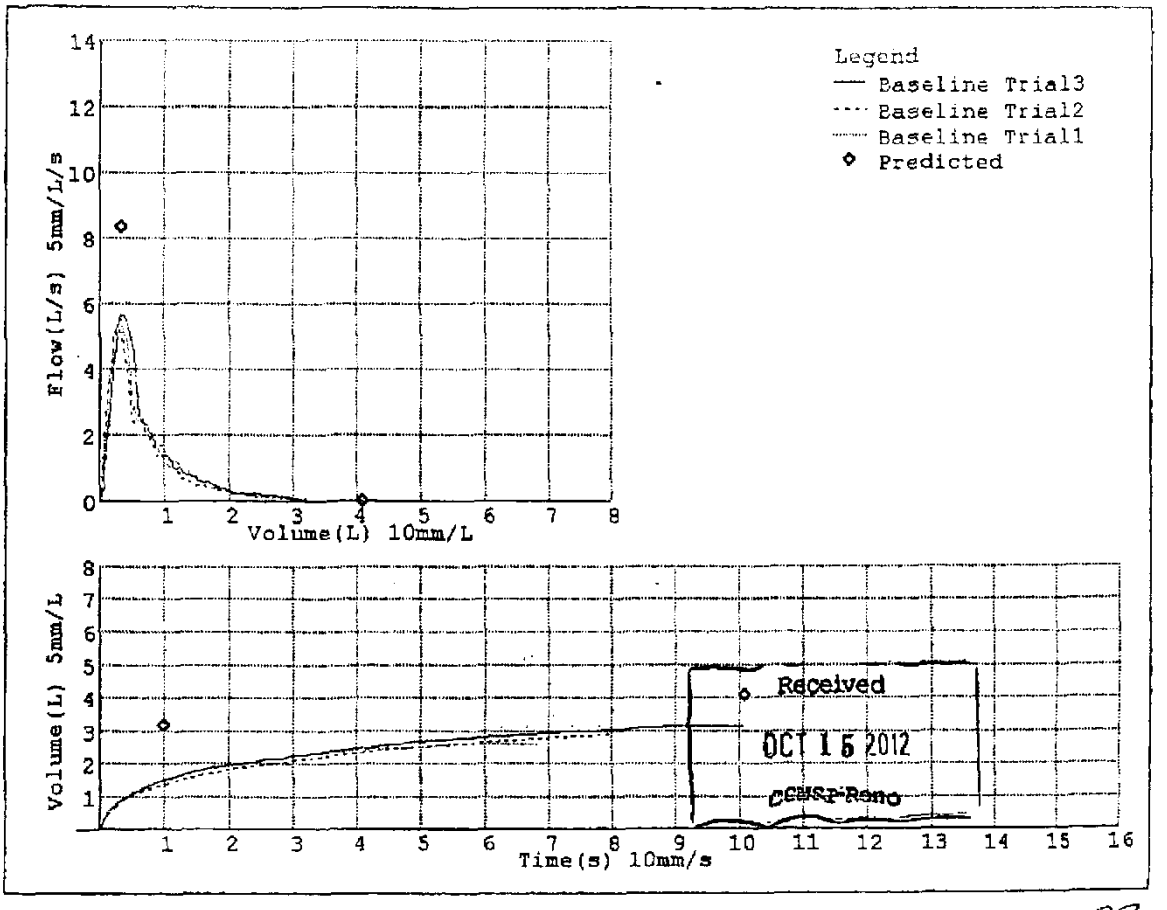

Received
OCT 15 2012
CCMSP-Reno

292 262 123

ACADIA MEDICAL GROUP

PROGRESS NOTES

Donald D. VanDyken, M.D.
Dulynn Hastings, M.D.
Katie Lydon, APN

Name: Daniel Demaranville Date: 3309 Chart # 134430

DOB: H: W: 211 T: P: 70 BP: 120/78 R: 18

HPI		
Location, quality, severity, duration, timing, context, modifying factors, associated signs and symptoms.		
ROS	WNL	See note
Const	☐	☐
Eyes	☐	☐
ENT/mouth	☐	☐
CV	☐	☐
Resp	☐	☐
GI	☐	☐
GU	☐	☐
Musc	☐	☐
Skin/breasts	☐	☐
Neuro	☐	☐
Psych	☐	☐
Endo	☐	☐
Hem/lymph	☐	☐
Allerg/immun	☐	☐
PFSH	No chng	See note
Past	☐	☐
Family	☐	☐
Social	☐	☐
Exam	WNL	See note
Const	☐	☐
Eyes	☐	☐
ENT/mouth	☐	☐
Neck	☐	☐
Resp	☐	☐
CV	☐	☐
Chest (breasts)	☐	☐
GI (abdomen)	☐	☐
Lymph	☐	☐
GU	☐	☐
Musc	☐	☐
Skin	☐	☐
Neuro	☐	☐
Psych	☐	☐

No ✓: no review/exam

CC: Hx of phone for injection (R) hand

HPI: S.I.C. done
B x 3
Inj 25mg cc Kem 40 25cc 1% plain
Also cont g job, smoking
wanted Rx for patches
Rx Nicotine patch system 1/prn

A: Trigger finger 727.03
Tob addiction 305.1
GERD 530.81
Rectal hemo 3004

P: As above
RV 2 weeks

MEDICATIONS

Zantac 150mg PO
Lexapro 10mg PO
Flomax
Omeprazole
Diazepam 5mg PO

Received
OCT 15 2012
CCMSI-Reno

Couns/coord > 50% ☐ Total time: ____ min. Couns/coord time: ____ min.

Developed by the editors of FPM, Copyright © 1995, 1998 American Academy of Family Physicians. Physicians may photocopy for use in their own practices; all other rights reserved. "Two Tried-and-True Tools for E/M Documentation." Backer LA. Family Practice Management. October 2003:5 http://aafp.org/fpm/20030900/51twot.html.

AMG-051 REV 3/04

ACADIA MEDICAL GROUP

PROGRESS NOTES

Donald D. VanDyken, M.D.
Dulynn Hastings, M.D.
Katie Lydon, APN

Name: Daniel Demaranville Date: 6/10/09 Chart #: 134430

DOB: _____ H: ____ W: 217 T: ____ P: 70 BP: 130/[illegible] R: 18

HPI	
Location, quality, severity, duration, timing, context, modifying factors, associated signs and symptoms.	

ROS	WNL	See note
Const	☐	☐
Eyes	☐	☐
ENT/mouth	☐	☐
CV	☐	☐
Resp	☐	☐
GI	☐	☐
GU	☐	☐
Musc	☐	☐
Skin/breasts	☐	☐
Neuro	☐	☐
Psych	☐	☐
Endo	☐	☐
Hem/lymph	☐	☐
Allerg/immun	☐	☐

PFSH	No chng	See note
Past	☐	☐
Family	☐	☐
Social	☐	☐

Exam	WNL	See note
Const	☐	☐
Eyes	☐	☐
ENT/mouth	☐	☐
Neck	☐	☐
Resp	☐	☐
CV	☐	☐
Chest (breasts)	☐	☐
GI (abdomen)	☐	☐
Lymph	☐	☐
GU	☐	☐
Musc	☐	☐
Skin	☐	☐
Neuro	☐	☐
Psych	☐	☐

No ✓: no review/exam

CC: 74yr ♂ here for Flu ~~Dysthymia~~ Dysthymia ~~as~~ Dx

HPI: Difficult to rep for Chlorpen Med.
quit smoking!!
was on patch x 2 mos.
Feels better off cig.
Dind. not taking Nsd oxl.
" pers SEs. of citalopram
↑ WT
" pers retard of Wellbutrin
or trial of SI ssrs.
GI ↓
GU: OK.
E.D. ± if quits in half.
O- W NAD, NAD
OW
A- T2 DM 250.1
GERD 530.81
DLS 785.62
WT gain 783.1
P- Trial citalopram 20mg qD 30/3
Rec 4 wks.
Ex
WT loss

MEDICATIONS:
Zantac 150 mg bid
Lexapro 10mg qD
Flomax ?
0.4mg ?
Viagra ?
50mg PRN

Received
OCT 15 2012
CMCI-Reno

Couns/coord>50% ☐ Total time: _____ min. Couns/coord time: _____ min.

Developed by the editors of FPM, Copyright © 1995, 1998 American Academy of Family Physicians. Physicians may photocopy for use in their own practices; all other rights reserved.
"Two Tried-and-True Tools for E/M Documentation." Backer LA. *Family Practice Management*. October 2003; http://aafp.org/fpm/20030900/51twot.html.

AMG-051 REV 3/04

Specimen #	Control/Req Nr	
282-134-0456-0	640043 76	Pg 1

LabCorp V 1.36

Fasting	Micro Source	Total Urine Volume	Report Status
Yes			S /Final

Date Collected	Time Collected	Date Entered	Date Reported
10/09/09	08:36	10/09/09	10/10/09

Clinical Information

Patient ID Number	Patient Phone Number	Patient SSN
282380	775-345-6530	

Patient Name: DEMARANVILLE, DANIEL
Sex: M
Date of Birth: 10/04/34
Patient Address: PO BOX 261
VERDI NV 89439

Account
27896221
Acadia Medical Group
00
900 Ryland St
Reno NV 89502

775-786-3555
NPI: 1710988167 UPIN: B43018
PHY NAME: VANDYKEN,

Comments
PATN AGE: 075/00/05

Tests Requested: CBC With Differential/Platelet; Comp. Metabolic Panel (14); Urinalysis, Routine; Lipid Panel; Prostate-Specific Ag, Serum; Venipuncture;

A courtesy copy of this report has been sent to
CONCENTRA MED SERV MILL LAB.

TESTS	RESULT	FLAG	UNITS	REFERENCE INTERVAL	LAB
CBC With Differential/Platelet					
WBC	6.6		x10E3/uL	4.0 - 10.5	01
RBC	4.83		x10E6/uL	4.10 - 5.60	01
Hemoglobin	16.0		g/dL	12.5 - 17.0	01
Hematocrit	48.7		%	36.0 - 50.0	01
MCV	**101**	**High**	fL	80 - 98	01
MCH	33.2		pg	27.0 - 34.0	01
MCHC	32.9		g/dL	32.0 - 36.0	01
RDW	13.9		%	11.7 - 15.0	01
Platelets	189		x10E3/uL	140 - 415	01
Neutrophils	58		%	40 - 74	01
Lymphs	30		%	14 - 46	01
Monocytes	10		%	4 - 13	01
Eos	2		%	0 - 7	01
Basos	0		%	0 - 3	01
Neutrophils (Absolute)	3.8		x10E3/uL	1.8 - 7.8	01
Lymphs (Absolute)	2.0		x10E3/uL	0.7 - 4.5	01
Monocytes(Absolute)	0.7		x10E3/uL	0.1 - 1.0	01
Eos (Absolute)	0.1		x10E3/uL	0.0 - 0.4	01
Baso (Absolute)	0.0		x10E3/uL	0.0 - 0.2	01
Comp. Metabolic Panel (14)					
Glucose, Serum	98		mg/dL	65 - 99	01
BUN	22		mg/dL	5 - 26	01
Creatinine, Serum	**1.42**	**High**	mg/dL	0.76 - 1.27	01
eGFR	**49**	**Low**	mL/min/1.73	>59	
eGFR AfricanAmerican	**59**	**Low**	mL/min/1.73	>59	
Note: Persistent reduction for 3 months or more in an eGFR <60 mL/min/1.73 m2 defines CKD. Patients with eGFR values >/=60 mL/min/1.73 m2 may also have CKD if evidence of persistent proteinuria is present. Additional information may be found at www.kdoqi.org.					
BUN/Creatinine Ratio	15			8 - 27	
Sodium, Serum	141		mmol/L	135 - 145	01
Potassium, Serum	4.5		mmol/L	3.5 - 5.2	01
Chloride, Serum	102		mmol/L	97 - 108	01
Carbon Dioxide, Total	24		mmol/L	20 - 32	01
Calcium, Serum	9.4		mg/dL	8.5 - 10.6	01

FINAL REPORT

© 2007 Laboratory Corporation of America® Holdings All Rights Reserved

DEMARANVILLE, DANIEL 282380 Received 282-134-0456-0 Seq# 8369 10-10-09 09:05ET

OCT 15 2012
CCMSI-Reno

OCT 12 2009

295 265 Universal#2 560281s1

Specimen #	Control/Req Nr	
282-134-0456-0	640043 576	Pg 2

LabCorp V 1.36

Fasting	Micro Source	Total Urine Volume	Report Status
Yes			S /Final

Date Collected	Time Collected	Date Entered	Date Reported
10/09/09	08:36	10/09/09	10/10/09

Clinical Information

Patient ID Number	Patient Phone Number	Patient A&N
282380	775-345-6530	

Patient Name	Sex	Date of Birth
DEMARANVILLE, DANIEL	M	10/04/34

Patient Address PO BOX 261
VERDI NV 89439

Account
27896221
Acadia Medical Group
00
900 Ryland St
Reno NV 89502

775-786-3555
NPI: 1710988167 UPIN: B43018
PHY NAME: VANDYKEN,

Comments
PATN AGE: 075/00/05

Tests Requested CBC With Differential/Platelet; Comp. Metabolic Panel (14); Urinalysis, Routine; Lipid Panel; Prostate-Specific Ag, Serum; Venipuncture;

TESTS	RESULT	FLAG	UNITS	REFERENCE INTERVAL	LAB
Protein, Total, Serum	6.5		g/dL	6.0 - 8.5	01
Albumin, Serum	4.8		g/dL	3.5 - 4.8	01
Globulin, Total	1.7		g/dL	1.5 - 4.5	
A/G Ratio	**2.8**	**High**		1.1 - 2.5	
Bilirubin, Total	0.4		mg/dL	0.1 - 1.2	01
Alkaline Phosphatase, S	41		IU/L	25 - 160	01
AST (SGOT)	27		IU/L	0 - 40	01
ALT (SGPT)	29		IU/L	0 - 55	01
Urinalysis, Routine					
Urinalysis Gross Exam					01
Specific Gravity	1.025			1.005 - 1.030	01
pH	6.0			5.0 - 7.5	01
Urine-Color	Yellow			Yellow	01
Appearance	Clear			Clear	01
WBC Esterase	Negative			Negative	01
Protein	Negative			Negative/Trace	01
Glucose	Negative			Negative	01
Ketones	Negative			Negative	01
Occult Blood	Negative			Negative	01
Bilirubin	Negative			Negative	01
Urobilinogen,Semi-Qn	0.2		mg/dL	0.0 - 1.9	01
Nitrite, Urine	Negative			Negative	01
Microscopic Examination					
Microscopic follows if indicated.					01
Lipid Panel					
Cholesterol, Total	198		mg/dL	100 - 199	01
Triglycerides	96		mg/dL	0 - 149	01
HDL Cholesterol	56		mg/dL	>39	01
Comment					01
According to ATP-III Guidelines, HDL-C >59 mg/dL is considered a negative risk factor for CHD.					
VLDL Cholesterol Cal	19		mg/dL	5 - 40	
LDL Cholesterol Calc	**123**	**High**	mg/dL	0 - 99	
Prostate-Specific Ag, Serum					
Prostate Specific Ag, Serum	0.4		ng/mL	0.0 - 4.0	01
Roche ECLIA methodology.					

According to the American Urological Association, Serum PSA should

FINAL REPORT

© 2007 Laboratory Corporation of America® Holdings All Rights Reserved

DEMARANVILLE, DANIEL 282380 282-134-0456-0 Seq# 8369 10-10-09 09:05ET

Received OCT 16 2012 CCMSI Reno

OCT 12 2009

127

296 266

Universal #2 56026 1a1

ACADIA MEDICAL GROUP

PROGRESS NOTES

Donald D. VanDyken, M.D.
Dulynn Hastings, M.D.
Katie Lydon, APN

Name: Daniel Demaranville Date: 10/13/09 Chart # 134430

DOB: H: W: 218 T: P: 76 BP: 130/68 Ht 5'9

HPI: Location, quality, severity, duration, timing, context, modifying factors, associated signs and symptoms.

ROS	WNL	See note
Const	☐	☐
Eyes	☐	☐
ENT/mouth	☐	☐
CV	☐	☐
Resp	☐	☐
GI	☐	☐
GU	☐	☐
Musc	☐	☐
Skin/breasts	☐	☐
Neuro	☐	☐
Psych	☐	☐
Endo	☐	☐
Hem/lymph	☐	☐
Allerg/immun	☐	☐

PFSH	No chng	See note
Past	☐	☐
Family	☐	☐
Social	☐	☐

Exam	WNL	See note
Const	☐	☐
Eyes	☐	☐
ENT/mouth	☐	☐
Neck	☐	☐
Resp	☐	☐
CV	☐	☐
Chest (breasts)	☐	☐
GI (abdomen)	☐	☐
Lymph	☐	☐
GU	☐	☐
Musc	☐	☐
Skin	☐	☐
Neuro	☐	☐
Psych	☐	☐

No ✓: no review/exam

CC: Pt is here for 2 month F/U Bipolar, Drug Depression, DUI - 4 years ago

HP: Bipolar, Depression, DUI - 4 years ago

Suicide ↑ RFTs
" gen ↑ PSA
" ↑ LDL
↑ LDL ⊘ Tof
O - WN WD ON
A - ↑ RFTs 796.4
WT gain 783.1
6 ⊘ RFT, 580.81
DUS 708.62
P. Rev labs
OV as prev

MEDICATIONS
Citalopram
Zonegran
Tenofovir
150mg
Flomax
0.4mg
Viagra
50mg PRN

PHONE CALL
FOR DVD DATE 101509 TIME 231 A.M. P.M.
M. Dan Demeranville
OF Laura
PHONE 345.0530 FAX/CELL 233.4102
MESSAGE Pls look @ EKG, Had was done at work. Dr. there suggested he see a cardiologist but pt wants you to look at it first.
SIGNED
☐ TELEPHONED ☐ RETURNED YOUR CALL ☐ PLEASE CALL ☐ WILL CALL AGAIN ☐ CAME TO SEE YOU ☐ WANTS TO SEE YOU

thanks

PHONE CALL
FOR DATE A.M. P.M.
M.
OF
PHONE FAX/CELL
MESSAGE WITH YOU? WITH KT? If w/ you the week you get back? is it ok to do?
10-21-09 (N)
SIGNED
☐ TELEPHONED ☐ RETURNED YOUR CALL ☐ PLEASE CALL ☐ WILL CALL AGAIN ☐ CAME TO SEE YOU ☐ WANTS TO SEE YOU

yes

BMP
N. Fast
c.c. pt.

Received
OCT 16 2012

min.

Developed by the editors of FPM. "Two Tried-and-True

practices; all other rights reserved. 0030900/51twot.html

AMG-051 REV 3/04

297

267

128

DEMARANVILLE,DANIEL
ID:

10/15/09 9:52:08

DEMARANVILLE,DANIEL
ID: 504-28-1477

10/15/09 9:52:08

D.O.B.: 10/04/1934 75 YEARS
MALE
Meds:
Class:
Loc: 12

Vent. Rate:	75 bpm
P Duration:	102 ms
QRS Duration:	152 ms
PR Interval:	166 ms
QT Interval:	408 ms
QTc Interval:	434 ms
P-R-T AXIS:	75° 104° 63°

SINUS RHYTHM
Low terminal QRS spatial velocity
Broad R or R' in V1 or V2
RIGHT BUNDLE BRANCH BLOCK

Summary: ABNORMAL

* Unconfirmed Analysis

Received
OCT 15 2012
CPMST-Reno

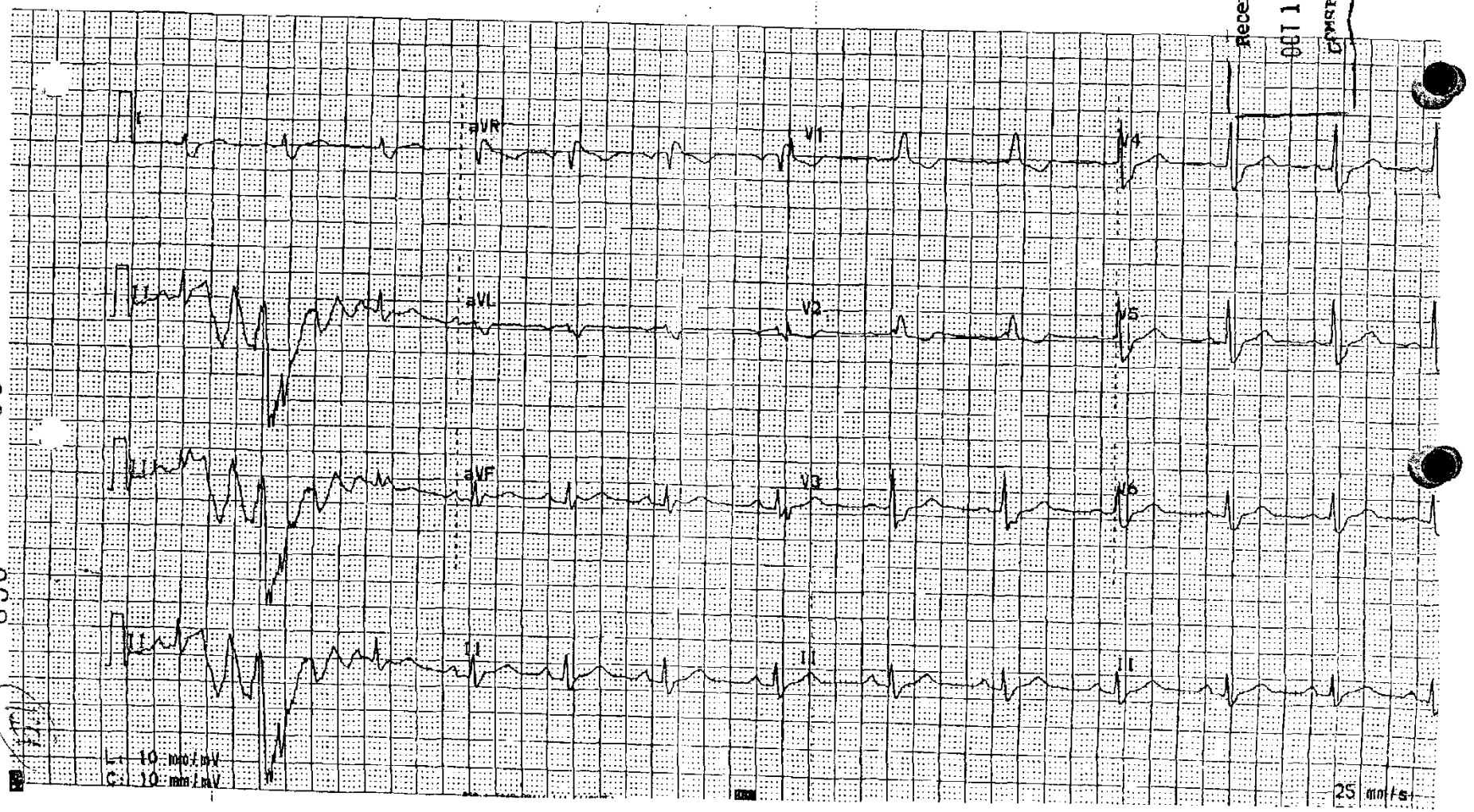

298
268

SA 310

Specimen #	Control/Req #		
294-134-0536-0	6400437[illegible]93	Pg 1	

LabCorp V 1.36

Fasting	Micro Source	Total Urine Volume	Report Status
No			S /Final

Date Collected	Time Collected	Date Entered	Date Reported
10/21/09	11:55	10/21/09	10/22/09

Clinical Information

Patient ID Number	Patient Phone Number
282380	775-345-6530

Patient Name	Sex	Date of Birth
DEMARANVILLE, DANIEL	M	10/04/34

Patient Address PO BOX 261
VERDI NV 89439

Comments
PATN AGE: 075/00/17

Account
27896221
Acadia Medical Group
00
900 Ryland St
Reno NV 89502

775-786-3555
NPI: 1710988167 UPIN: B43018
PHY NAME: VANDYKEN,

Tests Requested Basic Metabolic Panel (8); Venipuncture;

A courtesy copy of this report has been sent to the patient.

NON fast

TESTS	RESULT	FLAG	UNITS	REFERENCE INTERVAL	LAB
Basic Metabolic Panel (8)					
Glucose, Serum	**118**	**High**	mg/dL	65 - 99	01
BUN	20		mg/dL	5 - 26	01
Creatinine, Serum	1.27		mg/dL	0.76 - 1.27	01
eGFR	**55**	**Low**	mL/min/1.73	>59	
eGFR AfricanAmerican	>59		mL/min/1.73	>59	
Note: Persistent reduction for 3 months or more in an eGFR <60 mL/min/1.73 m2 defines CKD. Patients with eGFR values >/=60 mL/min/1.73 m2 may also have CKD if evidence of persistent proteinuria is present. Additional information may be found at www.kdoqi.org.					
BUN/Creatinine Ratio	16			8 - 27	
Sodium, Serum	138		mmol/L	135 - 145	01
Potassium, Serum	4.1		mmol/L	3.5 - 5.2	01
Chloride, Serum	101		mmol/L	97 - 108	01
Carbon Dioxide, Total	25		mmol/L	20 - 32	01
Calcium, Serum	9.3		mg/dL	8.5 - 10.6	01

01 PD LabCorp Phoenix Dir: Frank Ryan, PhD
3930 E Watkins Suite 300, Phoenix, AZ 85034-7251
For inquiries, the physician may contact **Branch: 800-765-2755 Lab: 602-454-8000**

LAST PAGE OF REPORT

Received
OCT 15 2012
CCMSF-Reno

OCT 22 2009

FINAL REPORT

© 2007 Laboratory Corporation of America® Holdings
All Rights Reserved

DEMARANVILLE, DANIEL 282380 294-134-0536-0 Seq# 8482 10-22-09 09:05ET

130

299 269 Universal #2 560281a1

SA 311

ACADIA MEDICAL GROUP

PROGRESS NOTES

Donald D. VanDyken, M.D.
Dulynn Hastings, M.D.
Katie Lydon, APN

Name: Daniel Demaranville Date: 10-24-09 Chart #: 13443D

DOB: H: W: 216 T: P: 70 BP: 14/60 98

HPI
Location, quality, severity, duration, timing, context, modifying factors, associated signs and symptoms.

ROS	WNL	See note
Const	☐	☐
Eyes	☐	☐
ENT/mouth	☐	☐
CV	☐	☐
Resp	☐	☐
GI	☐	☐
GU	☐	☐
Musc	☐	☐
Skin/breasts	☐	☐
Neuro	☐	☐
Psych	☐	☐
Endo	☐	☐
Hem/lymph	☐	☐
Allerg/immun	☐	☐

PFSH	No chng	See note
Past	☐	☐
Family	☐	☐
Social	☐	☐

Exam	WNL	See note
Const	☐	☐
Eyes	☐	☐
ENT/mouth	☐	☐
Neck	☐	☐
Resp	☐	☐
CV	☐	☐
Chest (breasts)	☐	☐
GI (abdomen)	☐	☐
Lymph	☐	☐
GU	☐	☐
Musc	☐	☐
Skin	☐	☐
Neuro	☐	☐
Psych	☐	☐

No ✓: no review/exam

CC: 75 yo ♂ here to go over CXR results

HPI: Reviewed labs — [illegible]

dated & nl

" ↓ GFR mean nl

" no ↑ in BUN (only P.K.) in [illegible] 4 years. Renewed prev RX for Celexa

Needs citalopram refill

is too happy c citalopram

is less angry/reactive. ↓ PSOB and ↓ 0.4 mg

O: WD, WP, Well, NAD

Affect nl

A: 1. Abn EKG stable 794.31

2. GERD 530.81

3. ED 302.72

4. DJD 788.62

5. Depression / Anger disorder

P: Cont meds

Citalopram 20 mg qD

RTC PP 1/10

MEDICATIONS

Citalopram 20mg qD

Celexa 150mg qD

Flomax 0.4 mg qD

Viagra 50mg PRN

Needs refill

Received
OCT 15 2012
CCMST-Reno

Couns/coord>50% ☐ Total time: _____ min. Couns/coord time: _____ min.

Developed by the editors of *FPM*. Copyright © 1995, 1998 American Academy of Family Physicians. Physicians may photocopy for use in their own practices; all other rights reserved.
"Two Tried-and-True Tools for E/M Documentation." Backer LA. *Family Practice Management*. October 2003. http://aafp.org/fpm/20030900/51twot.html.

MG-051 REV 3/04

131

300 270

ACADIA MEDICAL GROUP

HISTORY AND PHYSICAL EXAMINATION

Name: DANIEL E. DeMARANVILLE Date: 1-26-10

Considering what is normal for you:
Please read each line and circle **bolded** areas of difficulty or fill in ____

Review of systems:

- EENT: Have you had any problems with your: **eyes, ears, nose or throat?**
- Pulm: Have you had any problems with: **breathing, coughing or phlegm?** Do you ever: **cough up blood?**
- Cardio: Have you had ~~any: chest~~ **pains, palpitations (unusual heart beats)**, or ~~**difficulty breathing (with exercise or when lying down?)**~~ Have you had any **calf pain** when you walk? x 5 yrs. ø Δ. Morning wheezing full of wood
- GI: Have you had any problems with: **your stomach or digestion, nausea or vomiting, or with your bowels such as: diarrhea, constipation, hemorrhoids or blood in your stool?**
- If you are over 50, when was your last flexible sigmoidoscopy or colonoscopy? 2009
- GU: Are you having any problems with **urination?** YES Flomax ±
  - Men: do you have trouble starting your stream or emptying your bladder fully? YES
  - Women: do you **leak urine** when you cough, sneeze, laugh or strain?
- GYN: (for women only): Do you do monthly **breast self-exams**? Found any lumps?
  - Are you having any problems with your **menstrual period?**
  - When was your last **normal menstrual period?** ____
  - What do you use for **Contraception?** ____
- For both sexes: Do you have any sexual problems or concerns? Y (N)
  - Do you need any information about sexually transmitted diseases? Y (N)
- Musculoskeletal: Do you have any problems with your: **muscles, bones, or joints?**
- Exercise: How much **aerobic exercise** do you get each week? 0
- Neuro: Do you have any **unusual headaches?** Do you have any: **numbness, weakness tingling, seizures, passing out, or vision changes?** NO
- Endo: Do you have: a feeling that you are **warmer (or colder)** than most other people? NO
  - Do you feel unusually **tired?** SOMETIMES
  - Do you have any problems with your: **skin, hair, or nails?** NO
- Sleep: Do you have any problems **sleeping?** NO
- Psych: Do you have any problems with feeling **depressed, "blue", anxious or panicked?** NO
  - Do you feel: **helpless, hopeless, or suicidal?** NO
  - Do you have problems with: **concentrating** or with **having fun?** NO

- UPDATES: (for the physician to do): (check if done)
- Past medical and past surgical history:
- Social history:
- Family history:

Received
OCT 16 2012
CCMSI-Reno

©2003 Donald D. VanDyken, M.D.

Name: [illegible]
Chart 134430
age 75 DOB 10/4/34

Physical Exam Form

Date 1/26/10 BP 130/68 Pulse 76 / min Resp: 18 / min Wt: 212 lbs Ht: 69

Meds:
Zantac 150 mg tid
Lasix
Flomax 0.4 mg qd
Citalopram 20 mg qd
Viagra 50 mg PRN

General/Head and Neck	WD ☒ WN ☒ A &OX4 ☐ In NAD ☒
Head/ Scalp nl ☒	Eyes PERRL ☒ Fundi nl ☐ EOMI ☒
Ears—TM nl ☐ Canals nl ☒ L pert	Nose nl ☒
Mouth/Teeth nl ☒	Pharynx nl ☒
Neck Thyroid nl ☒ Nodes nl ☒	Carotids No Bruits ☒ Pulses nl ☒ 1+
Chest	
Lungs CTAP ☒ No R/W/C ☒	Breasts/Nipples nl ☐ No Masses d/c ☐ Symm ☐
Heart RRR ☒ No M/R/G ☒	Axillary Nodes nl ☐
Ribs nl ☒	Chest Wall nl ☒ No CVAT ☒ No Spine TTP ☒
Abdomen	
Bowel Sounds nl ☒ No Masses ☒ Non-Tender ☒	
No Abd/Renal Bruits ☒	
LKKS nl ☒	
Male	
Scrotum nl ☒	Testes nl ☒ L atrophy
Penis nl ☒ Circumcised ☒	Prostate nl ☐
No Hernias ☒	Anorectal nl ☐
Female	
Vulva nl ☐	Vagina nl ☐
Cervix nl ☒ No CMT ☐ Pap Done ☐	Uterus nl Size ☐ Ante Straight Retro Smooth No Masses ☐
Adenexa nl ☐ N.T. ☐ No Masses ☐	No Cystocele/ Rectocele ☐
Ano-Rectal nl ☐	STD (GC Chl RPR HIV Hep) Done ☐
Skin	
Moles nl ☒ darker spot mid upper chest	No Abnl Lesions ☒
Extremities	
Pulses nl: Radial ☐ P.T. ☐ D.P. ☒	No Edema ☒
Cyanosis None ☒	Clubbing None ☒
Joints nl ☒ Full ROM ☒	Back nl ☒
Neuro	
Motor/Strength nl ☒	Reflexes: Cerebellar nl ☒ DTRs nl ☒
Sensation nl ☒ A&Ox4 ☒	Gait nl ☒
Cranial Nerves II-XII Grossly Intact ☒	

Assessment:			Plan:
1) Melanotic Neoplasm	7852	PFT ☐	
2) GERD	8058	CBC ☐	1) Remove soon
3) DJD	7862	CMP ☐	2) Zantac 300 qPM 10/5
4) Benign Hypertrophy	3004	Lipids ☐	3) Flomax 0.4 qPM
5) Depression		UA ☐	4) Citalopram 20 qPM
6) GW		PSA ☐	5)
7) Deconditioned		Hypothyrd ☐	6)
8) E.D.		Arth Panel ☐	7) Exp
9) COPD		LFTs ☐	8)
10) Microhematuria		Hep. Panel ☐	9)
11) HTN mild		Hemclt X3 ☐	10)
12)		Mammo ☐	11) Dexa 1/15/13
13)		Dexa ☐	12)
14)		Echo ☐	13) Rev 3 mo
15)		EKG ☐	14)
		ETT ☐	15)
		Thallium ☐	

Received
OCT 15 2012
CCMSI-Reno

AMG 50 (10/03)

302 272 133

To: joan c ma CONCE...RA MED SERV MILL LAB

LabCorp

Specimen #	Type	Primary Lab	Report Status	
273-134-0039-0	R	PD	Final	PG 1

03 01

Additional Information: TIME 0831

DOB: 10/04/34
FASTING

Clinical Information: 1/31/2011 6:22ET

Physician ID	Patient ID	TVOL
BETZ		0000

Patient Name: 775-345-6530 DEMARANVILLE,DANIEL
Sex: M
Age (Yr/Mo): 075.11

Pat Add: PO BOX 261
VERDI , NV 89439-

Account: CONCENTRA MED SERV MILL LAB 27625491
00
1530 EAST 6TH STREET 00
RENO ,NV 89512-
775-322-5757 NVR

Date Collected	Date Entered	Date Reported	
09/30/10	09/30/10	10/01/10	INQY

TESTS	RESULT	FLAG	UNITS	REFERENCE INTERVAL	LAB
CMP14+LP+CBC/D/Plt+UA					
Chemistries					01
Glucose, Serum	96		mg/dL	65 - 99	01
BUN	20		mg/dL	5 - 26	01
Creatinine, Serum	1.34	H	mg/dL	0.76 - 1.27	01
eGFR	52	L	mL/min/1.73	>59	
eGFR AfricanAmerican	>59		mL/min/1.73	>59	
Note: Persistent reduction for 3 months or more in an eGFR <60 mL/min/1.73 m2 defines CKD. Patients with eGFR values >/=60 mL/min/1.73 m2 may also have CKD if evidence of persistent proteinuria is present. Additional information may be found at www.kdoqi.org.					
BUN/Creatinine Ratio	15			8 - 27	
Sodium, Serum	140		mmol/L	135 - 145	01
Potassium, Serum	4.2		mmol/L	3.5 - 5.2	01
Chloride, Serum	103		mmol/L	97 - 108	01
Carbon Dioxide, Total	22		mmol/L	20 - 32	01
Calcium, Serum	9.2		mg/dL	8.6 - 10.2	01
Protein, Total, Serum	6.7		g/dL	6.0 - 8.5	01
Albumin, Serum	4.2		g/dL	3.5 - 4.8	01
Globulin, Total	2.5		g/dL	1.5 - 4.5	
A/G Ratio	1.7			1.1 - 2.5	
Bilirubin, Total	0.6		mg/dL	0.0 - 1.2	01
Alkaline Phosphatase, S	45		IU/L	25 - 160	01
AST (SGOT)	32		IU/L	0 - 40	01
ALT (SGPT)	27		IU/L	0 - 55	01
					01
Lipids					01
Cholesterol, Total	182		mg/dL	100 - 199	01
Triglycerides	65		mg/dL	0 - 149	01
HDL Cholesterol	60		mg/dL	>39	01
Comment					01
According to ATP-III Guidelines, HDL-C >59 mg/dL is considered a negative risk factor for CHD.					
VLDL Cholesterol Cal	13		mg/dL	5 - 40	
LDL Cholesterol Calc	109	H	mg/dL	0 - 99	
T. Chol/HDL Ratio	3.0		ratio units	0.0 - 5.0	
					01
CBC, Platelet Ct, and Diff					01
WBC	5.8		x10E3/uL	4.0 - 10.5	01
RBC	4.91		x10E6/uL	4.10 - 5.60	01

Received
OCT 15 2012

This document contains private and confidential health information protected by state and federal law. If you have received this document in error, please call REPORT PHONE

DEMARANVILLE,DANIEL 1/32/2011

REPORT: CMS2-Reno

Laboratory Corporation of America® Holdings
All Rights Reserved

273 (134)

LabCorp

Specimen #	Type	Primary Lab	Report Status	
273-134-0039-0	R	PD	Final	PG 2

03 01

TIME 0831

Additional Information

DOB: 10/04/34
FASTING

Clinical Information 1/31/2011 6:22ET

Physician ID	Patient ID	
BETZ		TVOL 0000

Patient Name 775-345-6530
DEMARANVILLE,DANIEL

Sex M

Age (Yr/Mos) 075.11

Pat Addr PO BOX 261
VERDI , NV 89439-

Account
CONCENTRA MED SERV MILL LAB 27625491
00
1530 EAST 6TH STREET 00
RENO ,NV 89512-
775-322-5757 NVR

Date Collected	Date Entered	Date Reported	
09/30/10	09/30/10	10/01/10	INQY

TESTS	RESULT	FLAG	UNITS	REFERENCE INTERVAL	LAB
Hemoglobin	15.8		g/dL	12.5 - 17.0	01
Hematocrit	48.0		%	36.0 - 50.0	01
MCV	98		fL	80 - 98	01
MCH	32.2		pg	27.0 - 34.0	01
MCHC	32.9		g/dL	32.0 - 36.0	01
RDW	14.6		%	11.7 - 15.0	01
Platelets	195		x10E3/uL	140 - 415	01
Neutrophils	59		%	40 - 74	01
Lymphs	26		%	14 - 46	01
Monocytes	12		%	4 - 13	01
Eos	3		%	0 - 7	01
Basos	0		%	0 - 3	01
Neutrophils (Absolute)	3.3		x10E3/uL	1.8 - 7.8	01
Lymphs (Absolute)	1.5		x10E3/uL	0.7 - 4.5	01
Monocytes(Absolute)	0.7		x10E3/uL	0.1 - 1.0	01
Eos (Absolute)	0.2		x10E3/uL	0.0 - 0.4	01
Baso (Absolute)	0.0		x10E3/uL	0.0 - 0.2	01
Immature Granulocytes	0		%	0 - 1	01
Immature Grans (Abs)	0.0		x10E3/uL	0.0 - 0.1	01
					01
Urinalysis Gross Exam					01
Specific Gravity	1.020			1.005 - 1.030	01
pH	5.5			5.0 - 7.5	01
Urine-Color	Yellow			Yellow	01
Appearance	Clear			Clear	01
WBC Esterase	NEG			Negative	01
Protein	NEG			Negative/Trace	01
Glucose	NEG			Negative	01
Ketones	NEG			Negative	01
Occult Blood	NEG			Negative	01
Bilirubin	NEG			Negative	01
Urobilinogen,Semi-Qn	0.2		mg/dL	0.0 - 1.9	01
Nitrite, Urine	NEG			Negative	01
Microscopic Examination					01
Microscopic follows if indicated.					

01 PD LABCORP PHOENIX DIR: FRANK RYAN, PhD
3930 E WATKINS SUITE 300,PHOENIX, AZ 85034-7251

DIRECTOR: FRANK RYAN, PhD
For inquiries, the physician may contact BRANCH: 800-765-2755 LAB: 602-454-8000

This document contains private and confidential health information protected by state and federal law. If you have received this document in error, please call

REPORT PHONE

DEMARANVILLE,DANIEL

Received
OCT 15 2012
REPORT
CUST-Reno

1/32/2011

©2003 Laboratory Corporation of America® Holdings
All Rights Reserved

135

RENO HEART PHYSICIANS CARSON HEART PHYSICIANS

Consult

Patient: **Daniel E. Demaranville**
Age 76, Gender M
DOB 10/04/1934
MRN: 795450
Date: Jan 14 2011

Provider: Karen Clark MD

Chief Complaint

- Abnormal Cardiovascular Test

I am seeing Daniel Demaranville at the request of Concentra in consultation for: Abnormal EKG.

History of Present Illness

Patient has no previous cardiac history. Patient has not been having any symptoms.

[Mr. Demaranville is a 76 year old man w/ PMH of BPH who was sent for evaluation of an abnormal ECG. He works for a company that is contracted with the US Marshall's office. At his routine PE he had an ECG tjhat showed a RBBB and RAD. He was told he had this previously in 2004. He had a stress test and echocardiogram at that time. He was told it was all normal except for mild LVH on the echocardiogram. He denies any symptoms or limitations. He previously smoked but quit a few years ago. He states he cuts his own wood and walks without problems.

Cardiac Risk Factors: no diabetes mellitus, no peripheral vascular disease, no family history of coronary artery disease, no hypertension, no hyperlipidemia, no sedentary lifestyle and no sleep apnea.
Diet:. He consumes a diverse and healthy diet.
Weight Issues:. He does not have any weight concerns.
Exercise:. He exercises regularly.
Smoking:. He does not use tobacco.
Alcohol:. He consumes alcohol.

Daniel Demaranville presents with complaints of abnormal cardiovascular test, starting 6 years ago.
Previous Evaluation: stress test and echocardiogram.
Risk Factors: alcohol use and no smoking.
Family History: no COPD, no coronary disease, no diabetes, no hypertension, no peripheral vascular disease and no hyperlipidemia. (ECG)

DONALD M.D. VAN DYKEN

Review of Systems

Constitutional: no fever, no chills, not feeling poorly (malaise), not feeling tired (fatigue), no recent weight gain and no recent weight loss.
Eyes: no eyesight problems, no glaucoma and no cataracts.
ENT: no sinus problems.
Respiratory: no shortness of breath, no cough, no shortness of breath during exertion, no

Received
OCT 15 2012
CCMSI-Reno

JAN 24 2011

275

305

Consult

Patient : **Daniel E. Demaranville**
Age 76, Gender M
DOB 10/04/1934
MRN: 795450
Date: Jan 14 2011

Provider: Karen Clark MD

orthopnea and no PND.
The patient presents with complaints of wheezing. (in past which resolved with tobaCCO CESSATION).
Cardiovascular: see History of Present Illness
Gastrointestinal: heartburn, but no abdominal pain, no constipation, no diarrhea and no nausea.
Genitourinary: urinary hesitancy, but no dysuria.
Musculoskeletal: no arthralgias and no joint pain.
Integumentary: no skin lesions.
Neurological: no dizziness and no fainting.
Extremities: no edema.
Psychiatric: no sleep disturbances, no anxiety and no depression.
Hematologic: no tendency for easy bleeding.
Endocrine: no diabetes.
Other Systems: all other systems are negative.

Active Problems
- Abnormal Electrocardiogram 794.31

Past Medical History
- History of Benign Prostatic Hypertrophy 600.00
- History of Esophageal Reflux 530.81

Surgical History
- History of Back Surgery
- History of Hernia Repair

Family History
No Relevance / Noncontributory
- Family history of No Relevance / Noncontributory

Social History
Problems
- Alcohol Use
- Former Smoker V15.82

Current Meds
- Aspirin Low Dose 81 MG Oral Tablet; TAKE 1 TABLET DAILY; Status: ACTIVE
- Citalopram Hydrobromide 20 MG Oral Tablet; TAKE 1 TABLET DAILY; Status: ACTIVE
- Doxazosin Mesylate 4 MG Oral Tablet; TAKE 1 TABLET DAILY; Status: ACTIVE
- Ranitidine HCl 300 MG Oral Tablet; TAKE 1 TABLET DAILY AS DIRECTED; Status: ACTIVE
- Tamsulosin HCl 0.4 MG Oral Capsule; TAKE 1 CAPSULE Daily; Status: ACTIVE

Allergies
- Penicillins : Swelling;

Vitals
Vital Signs [Data Includes: Current Encounter]

	14Jan2011	14Jan2011

DONALD M.D. VAN DYKEN

Received
OCT 1 5 2012
CCMSI-Reno

JAN 2 4 2011

276

306

137

Consult

Patient : **Daniel E. Demaranville**
Age 76, Gender M
DOB 10/04/1934
MRN: 795450
Date: Jan 14 2011

Provider: Karen Clark MD

	10:22AM	10:16AM
Systolic	170	
Diastolic	90	
Heart Rate	94	
Smoking Status	Non-Smoker	Non-Smoker
Height	5 ft 11 in	5 ft 11 in
Weight	214 lb	214 lb
BMI	29.85 kg/m2	29.85 kg/m2
BSA	2.17 m2	2.17 m2

Physical Exam

General Appearance: The patient was alert, fully oriented, in no acute distress, well developed and well nourished. Race/Ethnicity: Caucasian.
HEENT: Eyes:. Pupils were equal in size, round, reactive to light, with normal accommodation. The extraocular movements were intact. The sclera and conjunctiva were normal. Head:. The head was normal in appearance. Voice: normal voice quality. Oral Pharynx: no abnormalities.
Neck: Examination of the neck was normal, the neck was not tender and no thyroid enlargement. Jugular Veins: JVP normal. Carotid Upstroke Normal.
Chest: The chest was normal in appearance and there was no tenderness on palpation.
Pulmonary: Normal respiratory rhythm and effort, clear bilateral breath sounds and clear to auscultation and percussion.
Cardiovascular: The PMI was palpated at the 5th LICS in the midclavicular line The apical impulse was normal. Rate: normal rate. Rhythm: regular. Heart sounds: normal S1, normal S2, no S3 heard, no S4 heard. No pericardial rub heard. Murmurs: no murmurs heard.
Abdomen: Normal bowel sounds, soft and not tender. No masses. No hepatosplenomegaly. Shape: non-prominent.
Vascular: Arterial pulses were normal on the right. Arterial pulses were normal on the left.
Carotid: right 2+, left 2+, no bruit heard over the right carotid, no bruit heard over the left carotid.
Dorsalis pedis: right 2+, left 2+.
Radial: right 2+, left 2+.
Abdominal Aorta The abdominal aorta was nonpalpable. Bruit not heard over the abdominal aorta.
Skin: Warm and dry.
Edema Detail: No pitting edema present.
Musculoskeletal: Normal movements of all extremities. Normal gait. Fingers: No clubbing of the fingernails, no cyanosis of the fingers.
Neuro: Oriented to person, place, and time. The motor exam was normal.
Psych: Affect is normal and mood is normal.

Tests

EKG:
I have ordered and interpreted this 12 lead EKG, and it reveals the following:
Rate: ventricular rate is 85 beats per minute.

DONALD M.D. VAN DYKEN

Received
OCT 1 5 2012
CCMSI Reno

JAN 2 4 2011

307 277 138

Consult

Patient : **Daniel E. Demaranville** Provider: Karen Clark MD
Age 76, Gender M
DOB 10/04/1934
MRN: 795450
Date: Jan 14 2011

Rhythm: sinus rhythm.
Bundle Branch Blocks: right bundle branch block.
QT Interval: normal.
Axis: right.
Blocks: none.

Assessment
1. Abnormal Electrocardiogram 794.31

Discussion/Summary

The patient presents with an abnormal EKG. In terms of my plan:. We will continue with current treatment. To further evaluate hisabnormal EKG, I have recommended the following: a stress echocardiogram. Risks, benefits and alternatives to this treatment plan were discussed with with the patient.

The above assessed problems are stable. The following chronic conditions are stable: Patient is to continue with the same medication regimen. Patient is to undergo the following testing: Stress echocardiogram. Patient is to follow-up sooner if clinical condition changes.

Thank you very much for allowing me to participate in the care of this patient. Thank you for requesting our opinion. If you have any questions, please do not hesitate to contact our office.

Signatures

Electronically signed by : Karen Clark, MD: Jan 14 2011 11:06AM (Author)
Reno Physician Signature Form: Karen Clark, MD

Copy for: cc: VanDyken, Donald
VanDyken, Donald



Received
OCT 15 2012
CCMSI-Reno

JAN 24 2011

278

308

ACADIA MEDICAL GROUP
HISTORY AND PHYSICAL EXAMINATION

Name: Daniel Demaranville Date: 1.31.11

Considering what is normal for you:

Please read each line and circle **bolded** areas of difficulty or fill in spaces to the double line below.

Review of systems:

- **EENT:** Do you have any problems with your: **eyes, ears, nose or throat?** NO.
- **Pulm:** Do you have any problems with: **breathing, coughing or phlegm?** Do you ever: **cough up blood?** NO
- **Cardio:** Do you have **chest pains, palpitations (unusual heart beats), or difficulty breathing (with exercise or when lying down?)** Do you have any **calf pain** when you walk? NO. — ~~P~~ 2 trips to wheelchair now ~~fall~~ sometimes. x wood. speak on blood going
- **GI:** Do you have any problems with: **your stomach or digestion, nausea or vomiting, or with your bowels such as: diarrhea, constipation, hemorrhoids or blood in your stool?**
- If you are over 50, when was your last flexible sigmoidoscopy or colonoscopy? 3 yrs ago.
- **GU:** Are you having any problems with **urination?** NO.
  Men: do you have trouble **starting your stream or emptying your bladder fully?** yes.
  Women: do you **leak urine** when you cough, sneeze, laugh or strain?
- **GYN:** (for women only): Do you do monthly **breast self-exams? Y N** Found any **lumps? Y N**
  Are you having any problems with your **menstrual period? Y/N**
  When was your last **normal menstrual period?** _____
  What do you use for **Contraception?** _____
- **For both sexes:** Do you have any sexual problems or concerns? **Y N**
  Do you need any information or want to be tested for sexually transmitted diseases? Y (N)
- **Musculoskeletal:** Do you have any problems with your: **muscles, bones, or joints?** leg cramps at night.
- **Exercise:** How many hours of **aerobic exercise** do you get each week? 0
- **Neuro:** Do you have any **unusual headaches?** Y (N) Do you have any: **numbness, weakness tingling, seizures, passing out, or vision changes?** NO.
- **Endo:** Do you have: a feeling that you are **warmer (or colder)** than most other people?
  Do you feel unusually **tired?** yes
  Do you have any problems with your: **skin, hair, or nails?** NO.
- **Sleep:** Do you have any problems **sleeping?** NO.
- **Psych:** Do you have any problems with feeling **depressed, "blue", anxious or panicked?** of course.
  Do you feel: **helpless, hopeless, or suicidal?** NO.
  Do you have problems with: **concentrating** or with **having fun?** NO.

When was your last Tetanus Shot? 7/10 Would you like a Shingles Vaccination? Y (N)
When was your last Flu Shot? _____
When was your last Pneumonia Shot? NO ?
Would you like any information on other vaccines? Y (N)

Received
1 6 2012
CCMSI Reno

- UPDATES: **(FOR THE PHYSICIAN TO DO):** (check if done)
- Past medical and past surgical history:
- Social history:
- Family history:

©2003 Donald D. VanDyken, M.D.

DONALD M.D. VAN DYKEN
140

Date: 1-31-11

Physical Exam Forms

7640-01 DOB 10.4.34

BP: 136/86 Pulse: 73 / min Resp: 20 / min Wt: 218 lbs Ht: 69 1/2 BMI:

General/Head and Neck	WD ☒ WN ☒ In NAD ☒
Head/Scalp nl ☒	Eyes PERRL ☒ Fundi nl ☐ EOMI ☒
Ears Tm nl ☒ Canals nl ☒	Nose nl ☒
Mouth/Teeth nl ☒	Pharynx nl ☒
Neck Thyroid nl ☒ Nodes nl ☒	Carotids No Bruits ☒ Pulses nl ☒
Chest	
Lungs CTAP ☒ No R/W/C ☒	Chest Wall nl ☒ No CVAT ☒ No Spine TTP ☒
Heart RRR ☒ No M/R/G ☒	Breasts/Nipples nl ☐ No Masses d/c ☐ Symm ☐
Ribs nl ☒	Axillary Nodes nl ☐
Abdomen	
Bowel Sounds ☒ No Masses ☒ Non-Tender ☒	
No Abd/Renal Bruits ☒	
LKKS nl ☒	
Female	
Vulva nl ☐	Vagina nl ☐
Cervix nl ☐ No CMT ☐ Pap Done ☐	Uterus nl Size ☐ Ante Straight Retro Smooth No Masses ☐
Adenexa nl ☐ N.T. ☐ No Masses ☐	No Cysotcele/Rectocele ☐
Ano-Rectal nl ☐	STD (GC Chl RPR HIV Hep HSVI/II)
Males	
Scrotum nl ☒	Testes nl ☒ L absent
Penis nl ☒	Prostate nl ☐
No Hernias ☒	Ano-rectal nl ☐ Refuses
Skin	
Moles nl ☒ No Rashes ☒	No Abnl Lesions ☒
Extremities	
Pulses nl: Radial ☐ P.T. ☐ D.P. ☒	No Edema ☒
Cyanosis None ☒	Clubbing None ☒
Joints nl ☒ Full ROM ☒	Back nl ☒
Neuro	
Motor/Strength nl ☒	Reflexes: Cerebellar nl ☒ DTRs nl ☒
Sensation nl ☒ A&Ox4 ☒	Gait ☒ nl ☒
Cranial Nerves II-XII Grossly Intact ☒	

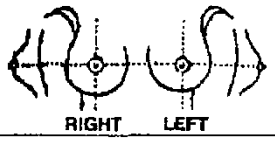

Meds: citalopram 20mg qQD Ranitidine 300mg qQD Tamsulosin 0.4mg qQPM + need Rx on all meds. + Refuses Flu Shot.

PT DID NOT BRING IN MEDS AS ADVISED MA

Assessment:		Plan:
1) Fatigue. 780.79	PFT ☐	
2) DJD. 788.62	CBC ☐	1)
3) OW. 278.02	CMP ☐	2) ~~Tamsulosin~~ Doxazosin 1mg qHS 8/11
4) GERD. 530.81	Lipids ☐	3)
5) depression	UA ☐	4) Ranitidine 300mg qPM 8/11
6) chest cramps/LAD	PSA ☒	5) Citalopram 20 qPM 90/P
7) NSL	Hypothyrd ☐	6)
8) COPD	LFTs ☐	7)
9) Marital difficulties	Hemclt X3 ☒	8)
10) EN	Mammo ☐	9) "Hold Me Tight"
11)	Dexa ☐	10) Couples (3)
12)	Echo ☐	11) Rx's
13)	EKG ☐	12)
14)	ETT ☐	13)
15)	Thallium ☐	14)
16) needs	CXR ☐	15)
	Immun ☒	16) DTAP

Received OCT 16 2012 CONFIDENTIAL 8-27-12

DONALD VAN DYKEN M.D.

141

280

310

RENO HEART PHYSICIANS
CARSON HEART PHYSICIANS

1500 E 2nd St Reno, NV 89502 | P. (775) 323-6700 | F. (775) 325-3489
343 Elm St., Ste. 400, Reno, NV 89520 | P. (775) 323-6700 | F. (775) 327-8191
2874 N. Carson St., Ste. 120, Carson City, NV 89706 | P. (775) 841-6700 | F. (775) 283-3260
www.RenoHeart.com

Cardiac Nuclear Medicine, Cardiac and Vascular Ultrasound Imaging

Stress Echocardiogram

Name: Demaranville, Daniel **Patient ID:** 795450 **Gender:** M
Exam Date: 03/28/2011 **HR:** 83 **Rhythm:** RBBB
DOB: 10/4/1934 **Age:** 76 Yrs **Left BP:** 140/84 mmHg
Height: 71 inches **Weight:** 214 lb **BSA:** 2.1 m^2
Reading Physician: Jerry Zebrack, MD **Sonographer:** B. Reagan
Referring Physician: Richard P. Ganchan, MD **CC:** Donald Van Dyken, MD
Indications: Abnormal EKG

TREADMILL, EKG, AND ECHO DATA SUMMARY **Echo exam quality: Adequate**

Exercise Protocol	
Protocol: Bruce	
Total minutes: 4:30	
Reason for stopping: Shortness of breath Back Pain	
FAI: +20	**METS:** 7.0

EKG Data
Pre-exercise EKG: Right bundle branch block. Normal sinus rhythm.
Exercise EKG: Right bundle branch block.

Heart Rate and Blood Pressure
Resting blood pressure: 140/84
Baseline heart rate: 88
Percent of Age-Predicted MHR: 99%
Blood pressure at peak exercise: 160/80
Maximum heart rate achieved: 143

EKG SUMMARY

1. Sensitivity is decreased because of RBBB.
2. No angina or anginal equivalent.
3. Exercise capacity was moderately decreased.
4. Normal heart rate response to exercise.
5. Normal blood pressure response to exercise.
6. No arrhythmias were observed.

ECHOCARDIOGRAM FINDINGS

- **Rest Echo Study:** Ejection fraction at rest = 57%. Cardiac chamber sizes and LV systolic function are normal at rest. No resting wall motion abnormalities noted.
- **Immediate Post-Exercise Echo Study:** Appropriate augmentation of left ventricular function after maximal exercise with decrease in end-systolic dimensions. No immediate post exercise abnormalities noted but technically suboptimal study.

IMPRESSION

Borderline EF

REST Score: 1.0



IMPOST Score: 1.0

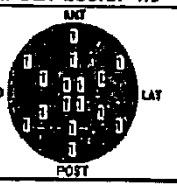

1 Normal	1 Hyperkinetic
2 Hypokinetic	3 Akinetic/
23 Hypokinetic (Mild)	4 Dyskinetic
2 Hypokinetic (Moderate)	5 Dilated and Thinned
2 Hypokinetic (Severe)	x Not Visualized
2 Hypokinetic (Borderline)	

Signature:

J Zebrack

Jerry N. Zebrack, M.D.
Electronically Signed 3/28/2011 3:04 PM

Received
OCT 15 2012
CCMSI-Reno

DONALD M.D. VAN DYKEN

FAXED
MAR 29 2011
By

ICAEL

MAR 29 2011 AO

142

311 281

Progress Note-Brief

Patient: **Daniel E. Demaranville**
Age 76, Gender M
DOB 10/04/1934
MRN: 795450
Date: Mar 30 2011

Provider: Richard P. Ganchan MD,FACC,FSCAI

Subjective

This 76-year-old man with right bundle branch block returns for clearance for working in security for the Federal Government.

He remains asymptomatic.

Review of stress echo reveals it to be normal.

Impression: Right bundle branch block. No evidence of organic heart disease. Disposition: Clear for security work without restriction.

Active Problems
Problems
- Abnormal Electrocardiogram 794.31

Current Meds
Medications
- Aspirin Low Dose 81 MG Oral Tablet; TAKE 1 TABLET DAILY; Status: ACTIVE
- Citalopram Hydrobromide 20 MG Oral Tablet; TAKE 1 TABLET DAILY; Status: ACTIVE
- Doxazosin Mesylate 4 MG Oral Tablet; TAKE 1 TABLET DAILY; Status: ACTIVE
- Ranitidine HCl 300 MG Oral Tablet; TAKE 1 TABLET DAILY AS DIRECTED; Status: ACTIVE
- Tamsulosin HCl 0.4 MG Oral Capsule; TAKE 1 CAPSULE Daily; Status: ACTIVE

Allergies
Medication
- Penicillins : Swelling;

Vitals
Vital Signs [Data Includes: Current Encounter]

	30Mar2011 08:19AM
Systolic	122, RUE, Sitting
Diastolic	68, RUE, Sitting



APR 0 7 2011

Received
OCT 1 5 2012
CCMSI-Reno

143

312 282

Progress Note-Brief

Patient : **Daniel E. Demaranville** Provider: Richard P. Ganchan
MD,FACC,FSCAI --
Age 76, Gender M
DOB 10/04/1934
MRN: 795450
Date: Mar 30 2011

Heart Rate	94
O2 Saturation	91, RA
Smoking Status	Non-Smoker
Height	5 ft 1 in
Weight	219 lb
BMI	41.38 kg/m2
BSA	1.96 m2

Signatures

Electronically signed by : Richard Ganchan, MD|FACC|FSCAI; Mar 30 2011 4:20PM
CC:
Donald Van Dyken, M.D.
Reno Heart Physicians Signature Form: Richard Ganchan, MD, FACC, FSCAI

Copy for:

DONALD VAN DYKEN M.D.

APR 0 7 2011

Received
OCT 1 6 2012
CCMSI-Reno

313 283 144

ACADIA MEDICAL GROUP
Acadia Medical Group
900 Ryland Street
Reno, NV 89502
Phone: 775-786-3555
Fax: 775-786-3088

DEMARANVILLE, DANIEL E
PO BOX 261
VERDI, NV 89439
Born 10/04/1934 (77 years)
775-345-6530

Visit Date	Visit With	Visit Description
2/14/2012	Lydon APN, Kathleen (3)	Physical

SOCIAL HISTORY
Smoking Status entered on 10/26/2011 1:33:45 PM recorded as Former smoker
ALCOHOL USE: moderate
DRUG USE:none
GAMBLING: none
MARITAL STATUS: married 16 yrs
OCCUPATION: court security office
TOBACCO USE: quit 2009

PAST MEDICAL HISTORY
172.9 Melanoma of skin, site unspecified
604.99 Other orchitis, epididymitis, and epididymo-orchitis, without mention of abscess
HOSPITALIZATIONS:colitis
SURGICAL HISTORY: L4 disc with staph infection, L orchiectomy, appy, T&A, phebo
IMMUNIZATIONS:
INFLUENZA-
PNEUMOVAX-
Toap-
SHINGLES-
HPV-
Hep A-
Hep B-
PPD-
C-scope- 2008
Mammo-
Dexa -
PSA-1996
Pap-
CXR - 1996

FAMILY HISTORY
Family History:
Htn: none
CAD: none
DM: none
Cancer: Sis - skin, Bro - lung, PU - lung
ETOH/ Drug Abuse: none
Psych: none
Endo: none
Renal: none
Pulm: none
Heme: none
Arth: M, Sis - knee
GI: none
Neuro: none

C/C OR REASON FOR VISIT
PHYSICAL

PLAN

VISIT CODE
PREVENTIVE MEDICINE EST. PATIENT AGES 65 (99397)

RX PRESCRIPTIONS
doxazosin 1 mg (1 tablet QHS) Qty: 90, Refills: 3
ranitidine HCl 300 mg (1 tablet BID) Qty: 180, Refills: 3
Viagra 100 mg (1 tablet DAILY) Qty: 6, Refills: 4
citalopram 20 mg (1 tablet as directed) Qty: 90, Refills: 3

E-SIGNATURES
Authenticated By: Lydon APN, Kathleen @ 2/14/2012 5:18 PM

Received
OCT 15 2012
CCMSI-Reno

ACADIA MEDICAL GROUP (ACADIA)
900 RYLAND STREET
RENO, NV 89502

DEMARANVILLE, DANIEL E
PO BOX 261
VERDI, NV 89439
DOB: 1934-10-04
Gender: Male
Patient ID (at Lab): 1776410

Group Number

Fecal Occult Blood (OCBLD)

Report Date:	Observation Date:	Specimin Source:	Specimin Received Date:
2012-02-14 16:07	2012-02-14 16:07		2012-02-14 16:07

Test Name:	Test Value:	Unit of Measure:	Range:	Flag	Lab
Occult Blood (OCBLD)	POSITIVE				ACADIA

Reviewed by: Lydon APN, Kathleen on 2/15/2012

ACADIA MEDICAL GROUP
HISTORY AND PHYSICAL EXAMINATION

Name: Daniel DeMaranville Date: 3-14-12

Considering what is normal for you:

Please read each line and circle **bolded** areas of difficulty or fill in spaces to the double line below.

Review of systems:

- **EENT:** Do you have any problems with your: **eyes, ears, nose or throat?** No
- **Pulm:** Do you have any problems with: **breathing, coughing or phlegm?** Do you ever: **cough up blood?** No
- **Cardio:** Do you have **chest pains, palpitations (unusual heart beats), or difficulty breathing (with exercise or when lying down?)** Do you have any **calf pain** when you walk? No
- **GI:** Do you have any problems with: **your stomach or digestion, nausea or vomiting, or with your bowels such as: diarrhea, constipation, hemorrhoids or blood in your stool?** No
- If you are over 50, when was your last flexible sigmoidoscopy or colonoscopy? 3-5 years ago
- **GU:** Are you having any problems with **urination?** No
  Men: do you have trouble **starting your stream or emptying your bladder fully?** Sometimes — totally empty on occasion
  Women: do you **leak urine** when you cough, sneeze, laugh or strain?
- **GYN:** (for women only): Do you do monthly **breast self-exams? Y N** Found any **lumps? Y N**
  Are you having any problems with your **menstrual period? Y/N**
  When was your last **normal menstrual period?** _____
  What do you use for Contraception? _____
- **For both sexes:** Do you have any sexual problems or concerns? Y (N)
  Do you need any information or want to be tested for sexually transmitted diseases? Y (N) — attend
- **Musculoskeletal:** Do you have any problems with your: **muscles, bones, or joints?** Sometimes
- **Exercise:** How many hours of **aerobic exercise** do you get each week? None
- **Neuro:** Do you have any **unusual headaches? Y (N)** Do you have any **numbness, weakness tingling, seizures, passing out, or vision changes?** No — walks 10-15' lifts weights
- **Endo:** Do you have: a feeling that you are **warmer (or colder)** than most other people? No
  Do you feel unusually **tired?** Sometimes
  Do you have any problems with your: **skin, hair, or nails?** No
- **Sleep:** Do you have any problems **sleeping?** No
- **Psych:** Do you have any problems with feeling **depressed, "blue", anxious or panicked?** No
  Do you feel: **helpless, hopeless, or suicidal?** No
  Do you have problems with: **concentrating** or with **having fun?** No

When was your last Tetanus Shot? 2011 Would you like a Shingles Vaccination? Y (N)
When was your last Flu Shot? Never
When was your last Pneumonia Shot? Never
Would you like any information on other vaccines? Y (N)

- UPDATES: **(FOR THE PHYSICIAN TO DO):** (check if done)
- Past medical and past surgical history: ✓
- Social history: ✓
- Family history: ✓

Received
OCT 15 2012
CCMSI-Reno

KLYOON APN

©2003 Donald D. VanDyken, M.D.

147

316 286

2/14/12 Daniel Vancaranvin

Physical Exam Forms

BP: / Pulse: / min Resp: / min Wt: 215 lbs Ht: 70 1/4 BMI:

Meds: Citalopram 20mg PO QD; Viagra 100mg; Ranitidine 300 1 po BID; Doxazosin 2mg 1 po QHS

General/Head and Neck thin skin	WD ☑ WN ☑ In NAD ☑
Head/Scalp nl ☑ @ hard c old sores	Eyes PERRL ☑ Fundi nl ☑ EOMI ☑
Ears Tm nl ☑ Canals nl ☑ RRG	Nose nl ☑
Mouth/Teeth nl ☑	Pharynx nl ☑
Neck Thyroid nl ☑ Nodes nl ☑	Carotids No Bruits ☑ Pulses nl ☑
Chest	
Lungs CTAP ☑ No R/W/C ☑	Chest Wall nl ☑ No CVAT ☑ No Spine TTP ☑
Heart RRR ☑ No M/R/G ☑	Breasts/Nipples nl ☑ No Masses d/c ☑ Symm ☑
Ribs nl ☑	Axillary Nodes nl ☑
Abdomen	
Bowel Sounds ☑ No Masses ☑ Non-Tender ☑	
No Abd/Renal Bruits ☑ large rectus diastasis	
LKKS nl ☑	
Female	RIGHT LEFT
Vulva nl ☑	Vagina nl ☑
Cervix nl ☑ No CMT ☑ Pap Done ☑	Uterus nl Size ☑ Ante Straight Retro Smooth No Masses ☑
Adenexa nl ☑ N.T. ☑ No Masses ☑	No Cysotcele/Rectocele ☑
Ano-Rectal nl ☑	
Males	@ ↓
Scrotum nl ☑	Testes nl ☑ missing @ testicle c scar
Penis nl ☑	Prostate nl ☑ 1+ ↑, no tenderness or nodularity
No Hernias ☑	Ano-rectal nl ☑ @ Quad
Skin	
Moles nl ☑ Rashes ☑	No Abnl Lesions ☑ — AK top of scalp
Extremities	
Pulses nl: Radial ☑ P.T. ☑ D.P. ☑	No Edema ☑
Cyanosis None ☑	Clubbing None ☑
Joints nl ☑ Full ROM ☑	Back nl ☑
Neuro	
Motor/Strength nl ☑	Reflexes: Cerebellar nl ☑ DTRs nl ☑
Sensation nl ☑ A&Ox4 ☑	Gait ☑ nl ☑ @ pre Bilateral hand tremors — HPC management of hands
Cranial Nerves II-XII Grossly Intact ☑	☐ CC Patient ☐ Dr ____ ☐ Dr ____

Assessment:				Plan:
1) Well @ exam	☑ CBC	☐ HSVI/II		1) f/u: the right sinus
2) GERD	☑ CMP	☐ Vag Probe		2) Citalopram 20 1 po QD 90/3 RF
3) DJD L/spine	☑ Lipids	☐ PFT		3) Ranitidine 300 1 po BID 180/3 RF
4) HTN	☑ UA	☐ Mammo		4) Doxazosin 2mg 1 po QHS 90/3 RF
5) Anxiety	☐ PSA	☐ Dexa		5) Viagra 100mg 1 po QD prn 6/5 RF
6) SK - AKs - scalp	☑ Hypothyrd	☐ Echo		6) Hot flashes — KLYNON APN
7) Hand tremors bilat	☐ LFTs	☐ EKG		7) Nitrogen to scalp for AKs
8)	☐ Hep. Panel	☐ ETT		8) Refer hand tremors for
9)	☐ Hemclt X1	☐ Thallium		9) Ret. pt to Beta blocker/dx
10)	☐ Hemclt X3	☐ CXR		10) of tremors — pt declined at
11)	☐ Vit D	☐ C-Scope		11) this time
12)	☐ I. Cal	☐ dT		12) — KLYNON APN
13)	☐ Testost	☐ TDAP		13)
14)	☐ A1C	☐ Pneumo		14)
15)	☐ GC Chly.	☐ Zosta		15)
16)	☐ RPR	☐ Flu		16)
17)	☐ HIV	☐ HPV		17)
	☐ Hep	☐		

Received
OCT 16 2012
CCMSI-Reno

148

ACADIA MEDICAL GROUP
Acadia Medical Group
900 Ryland Street
Reno, NV 89502
Phone: 775-786-3555
Fax: 775-786-3088

DEMARANVILLE, DANIEL E
PO BOX 261
VERDI, NV 89439
Born 10/04/1934 (77 years)
775-345-6530

Visit Date	Visit With	Visit Description
4/19/2012	Hastings MD, Dulynn (2)	Regular

MEDICATIONS HISTORY
doxazosin 2 mg (1 tablet NIGHTLY) Qty: 90, Refills: 3
ranitidine HCl 300 mg (1 tablet BID) Qty: 180, Refills: 3
Viagra 100 mg (1 tablet DAILY) Qty: 6, Refills: 4
citalopram 20 mg (1 tablet as directed) Qty: 90, Refills: 3

SOCIAL HISTORY
Smoking Status entered on 10/26/2011 1:33:45 PM recorded as Former smoker
ALCOHOL USE: moderate
DRUG USE:none
GAMBLING: none
MARITAL STATUS: married 16 yrs
OCCUPATION: court security office
TOBACCO USE: quit 2009

PAST MEDICAL HISTORY
172.9 Melanoma of skin, site unspecified
604.99 Other orchitis, epididymitis, and epididymo-orchitis, without mention of abscess
HOSPITALIZATIONS:colitis
SURGICAL HISTORY: L4 disc with staph infection, L orchiectomy, appy, T&A, phobo
IMMUNIZATIONS:
INFLUENZA-
PNEUMOVAX-
Tdap-
SHINGLES-
HPV-
Hep A-
Hep B-
PPD-
C-scope- 2008
Mammo-
Dexa -
PSA-1996
Pap-
CXR - 1996

FAMILY HISTORY
Family History:
Htn: none
CAD: none
DM: none
Cancer: Sis - skin, Bro - lung, PU - lung
ETOH/ Drug Abuse: none
Psych: none
Endo: none
Renal: none
Pulm: none
Heme: none

VITALS
DATE: 04/19/2012 TIME: 08:40:00 HT: 5'11 WT: 200 HR: 88 RESP: 18 BP (SYS/DIA): (L) 142/70

C/C OR REASON FOR VISIT
KENALOG INJECTION
htn
tremor

HISTORY OF PRESENT ILLNESS
» KENALOG INJECTION
pt here to get Kenalog injection. Pt states that he is doing well except his diffuse body aches from his polymyalgia rheumatica is worsening and he wants to get another kenalog shot which has helped significantly in the past.
» HTN
Htn- Doing well. NO side effects.
» TREMOR
Tremor worsening recently and worried as the last time he qualified to shoot his pistol he had difficulty holding gun steady.

PHYSICAL EXAM
» TREMOR
Tremor- Severe tremor shaking R > L hand when holds arm outstreached.
» KENALOG INJECTION
Gen. well-developed, well-nourished, alert, x4 no apparent distress.
Head normocephalic/atraumatic
Eyes PERRLA, EOMI, nonicteric.
Heart regular rate and rhythm without murmurs, rubs, or gallops.
Lungs clear auscultation bilaterally. No rhonchi, wheezing or crackles.
Abdomen soft, nontender, nondistended, positive bowel sounds. No hepatosplenomegaly. No rebound or guarding. No tenderness. No CVA tenderness.
Extremities show diffuse swollen, mildly tender joints of the shoulders bilaterally. Elbows bilaterally, hands bilaterally, low back, hips, and knees. He has good range of motion of all his extremities, but does have significant tremor as mentioned elsewhere.
Skin no rashes or lesions noted

DIAGNOSIS

Essential and other specified forms of tremor	333.1
Polymyalgia rheumatica	725
Osteoarthrosis, unspecified whether generalized or localized, hand	715.94
Essential hypertension, benign	401.1

PLAN

VISIT CODE
ESTABLISHED PATIENT M. COMPLEXITY (99214)

RX PRESCRIPTIONS
Toprol XL 25 mg (1 tablet DAILY) Qty: 30, Refills: 0

Received
OCT 15 2012
CCMSI-Reno

ACADIA MEDICAL GROUP
Acadia Medical Group
900 Ryland Street
Reno, NV 89502
Phone: 775-786-3555
Fax: 775-786-3088

DEMARANVILLE, DANIEL E
PO BOX 261
VERDI, NV 89439
Born 10/04/1934 (77 years)
775-345-6530

Visit Date	Visit With	Visit Description
4/19/2012	Hastings MD, Dulynn (2)	Regular

Arth: M, Sis - knee
GI: none
Neuro: none

doxazosin 2 mg (1 tablet NIGHTLY) Qty: 90, Refills: 0

PROCEDURES
INJECTIONS KENALOG 10 mg (J3301) x 8
INJECTIONS _INJ ADMIN CODE ADMINISTER INJ (96372)

FOLLOW UP
Follow-up in 2 weeks

REFERRALS
Neurology

NOTES
Add B Blocker for tremor. Discussed risk and benefits of kenalog. Pt want today. Refer to neuro re tremor.

E-SIGNATURES
Authenticated By: Hastings MD, Dulynn @ 4/19/2012 9:09 AM

Received
OCT 15 2012
CCMSI-Reno

LabCorp

LabCorp Phoenix (01)
3930 E Watkins Suite 300
Phoenix, AZ 850347251
602.454.8000
Director: Frank, Ryan PhD

DEMARANVILLE, DANIEL
PO BOX 261
Verdi, NV 89439-
DOB: 1934-10-04
Gender: Male
Patient Account # (at Lab): 27896221
Patient ID (at Lab): 3081375

Group Number
13182011130

A courtesy copy of this report has been sent to the patient.

CBC With Differential/Platelet (L:005009)

Report Date:	Observation Date:	Specimin Source:	Specimin Received Date:
2012-05-11 10:05	2012-05-10 08:25		2012-05-10 10:44

Test Name	Test Value	Unit of Measure	Range	Flag	Lab
WBC (L:005025)	7.8	x10E3/uL	4.0-10.5		01
RBC (L:005033)	4.87	x10E6/uL	4.10-5.60		01
Hemoglobin (L:005041)	16.2	g/dL	12.5-17.0		01
Hematocrit (L:005058)	48.5	%	36.0-50.0		01
MCV (L:015065)	100	fL	80-98	H	01
MCH (L:015073)	33.3	pg	27.0-34.0		01
MCHC (L:015081)	33.4	g/dL	32.0-36.0		01
RDW (L:105007)	13.7	%	11.7-15.0		01
Platelets (L:015172)	165	x10E3/uL	140-415		01
Neutrophils (L:015107)	62	%	40-74		01
Lymphs (L:015123)	21	%	14-46		01
Monocytes (L:015131)	14	%	4-13	H	01
Eos (L:015149)	3	%	0-7		01
Basos (L:015156)	0	%	0-3		01
Immature Cells (L:115398)					01
Neutrophils (Absolute) (L:015909)	4.7	x10E3/uL	1.8-7.8		01
Lymphs (Absolute) (L:015917)	1.6	x10E3/uL	0.7-4.5		01
Monocytes(Absolute) (L:015925)	1.1	x10E3/uL	0.1-1.0	H	01
Eos (Absolute) (L:015933)	0.3	x10E3/uL	0.0-0.4		01
Baso (Absolute) (L:015941)	0.0	x10E3/uL	0.0-0.2		01
Immature Granulocytes (L:015108)	0	%	0-2		01
Immature Grans (Abs) (L:015911)	0.0	x10E3/uL	0.0-0.1		01
NRBC (L:015945)					01
Hematology Comments: (L:015180)					01

Received
OCT 15 2012
CC:[illegible]

Comp. Metabolic Panel (14) (L:322000)

Report Date:	Observation Date:	Specimin Source:	Specimin Received Date:
2012-05-11 10:05	2012-05-10 08:25		2012-05-10 10:44

Test Name	Test Value	Unit of Measure	Range	Flag	Lab
Glucose, Serum (L:001032)	84	mg/dL	65-99		01
BUN (L:001040)	22	mg/dL	8-27		01
Creatinine, Serum (L:001370)	1.28	mg/dL	0.76-1.27	H	01
eGFR If NonAfrican Am (L:100791)	54	mL/min/1.73	>59	L	01

LabCorp Phoenix (01)
3930 E Watkins Suite 300
Phoenix, AZ 850347251
602.454.8000
Director: Frank, Ryan PhD

DEMARANVILLE, DANIEL
PO BOX 261
Verdi, NV 89439-
DOB: 1934-10-04
Gender: Male
Patient Account # (at Lab): 27896221
Patient ID (at Lab): 3081375

eGFR If Afrcn Am (L:100797)	62	mL/min/1.73	>59		01
BUN/Creatinine Ratio (L:011577)	17		10-22		01
Sodium, Serum (L:001198)	142	mmol/L	134-144		01
Potassium, Serum (L:001180)	4.3	mmol/L	3.5-5.2		01
Chloride, Serum (L:001206)	102	mmol/L	97-108		01
Carbon Dioxide, Total (L:001578)	18	mmol/L	20-32	L	01
Calcium, Serum (L:001016)	9.2	mg/dL	8.8-10.2		01
Protein, Total, Serum (L:001073)	6.6	g/dL	6.0-8.5		01
Albumin, Serum (L:001081)	4.3	g/dL	3.5-4.8		01
Globulin, Total (L:012039)	2.3	g/dL	1.5-4.5		01
A/G Ratio (L:012047)	1.9		1.1-2.5		01
Bilirubin, Total (L:001099)	0.6	mg/dL	0.0-1.2		01
Alkaline Phosphatase, S (L:001107)	45	IU/L	25-160		01
AST (SGOT) (L:001123)	28	IU/L	0-40		01
ALT (SGPT) (L:001545)	24	IU/L	0-55		01

Urinalysis, Routine (L:003038)

Report Date:	Observation Date:	Specimin Source:	Specimin Received Date:
2012-05-11 10:05	2012-05-10 08:25		2012-05-10 10:44

Test Name	Test Value	Unit of Measure	Range	Flag	Lab
Specific Gravity (L:013050)	1.026		1.005-1.030		01
pH (L:013078)	6.5		5.0-7.5		01
Urine-Color (L:013045)	Yellow		Yellow		01
Appearance (L:013052)	Clear		Clear		01
WBC Esterase (L:013185)	Negative		Negative		01
Protein (L:013094)	Negative		Negative/Trace		01
Glucose (L:013086)	Negative		Negative		01
Glucose Reflex (L:013087)					01
Ketones (L:013110)	Negative		Negative		01
Occult Blood (L:013102)	Negative		Negative		01
Bilirubin (L:013104)	Negative		Negative		01
Urobilinogen,Semi-Qn (L:013105)	0.2	mg/dL	0.0-1.8		01
Nitrite, Urine (L:013106)	Negative		Negative		01
Microscopic Examination (L:012237)					01

Microscopic follows if indicated.

Lipid Panel (L:303756)

Report Date:	Observation Date:	Specimin Source:	Specimin Received Date:
2012-05-11 10:05	2012-05-10 08:25		2012-05-10 10:44

Test Name	Test Value	Unit of Measure	Range	Flag	Lab

LabCorp Phoenix (01)
3930 E Watkins Suite 300
Phoenix, AZ 850347251
602.454.8000
Director: Frank, Ryan PhD

DEMARANVILLE, DANIEL
PO BOX 261
Verdi, NV 89439-
DOB: 1934-10-04
Gender: Male
Patient Account # (at Lab): 27896221
Patient ID (at Lab): 3081375

Cholesterol, Total (L:001065)	182	mg/dL	100-199		01
Triglycerides (L:001172)	86	mg/dL	0-149		01
HDL Cholesterol (L:011817)	61	mg/dL	>39		01

According to ATP-III Guidelines, HDL-C >59 mg/dL is considered a negative risk factor for CHD.

VLDL Cholesterol Cal (L:011916)	17	mg/dL	5-40		01
LDL Cholesterol Calc (L:012054)	104	mg/dL	0-99	H	01

Thyroid Panel With TSH (L:000620)

Report Date:	Observation Date:	Specimin Source:	Specimin Received Date:
2012-05-11 10:05	2012-05-10 08:25		2012-05-10 10:44

Test Name	Test Value	Unit of Measure	Range	Flag	Lab
TSH (L:004264)	1.880	uIU/mL	0.450-4.500		01
Thyroxine (T4) (L:001149)	5.2	ug/dL	4.5-12.0		01
T3 Uptake (L:001156)	40	%	24-39	H	01
Free Thyroxine Index (L:001164)	2.1		1.2-4.9		01

Prostate-Specific Ag, Serum (L:010322)

Report Date:	Observation Date:	Specimin Source:	Specimin Received Date:
2012-05-11 10:05	2012-05-10 08:25		2012-05-10 10:44

Test Name	Test Value	Unit of Measure	Range	Flag	Lab
Prostate Specific Ag, Serum (L:010334)	0.5	ng/mL	0.0-4.0		01

Roche ECLIA methodology.

According to the American Urological Association, Serum PSA should decrease and remain at undetectable levels after radical prostatectomy. The AUA defines biochemical recurrence as an initial PSA value 0.2 ng/mL or greater followed by a subsequent confirmatory PSA value 0.2 ng/mL or greater.
Values obtained with different assay methods or kits cannot be used interchangeably. Results cannot be interpreted as absolute evidence of the presence or absence of malignant disease.

Clinical Test Ordered By K LYDON (1710087341)

Reviewed by: Hastings MD, Dulynn on 5/11/2012

Received
OCT 15 2012
[illegible] Reno

ACADIA MEDICAL GROUP
Acadia Medical Group
900 Ryland Street
Reno, NV 89502
Phone: 775-786-3555
Fax: 775-786-3088

DEMARANVILLE, DANIEL E
PO BOX 261
VERDI, NV 89439
Born 10/04/1934 (77 years)
775-345-6530

Visit Date	Visit With	Visit Description
5/29/2012	Lydon APN, Kathleen (3)	Regular

ALLERGIES
Penicillins

MEDICATIONS HISTORY
Kenalog 40 mg/mL (1 mL as directed) Qty: 1, Refills: 0
Toprol XL 25 mg (1 tablet DAILY) Qty: 30, Refills: 0
doxazosin 2 mg (1 tablet NIGHTLY) Qty: 90, Refills: 0
ranitidine HCl 300 mg (1 tablet BID) Qty: 180, Refills: 3
Viagra 100 mg (1 tablet DAILY) Qty: 8, Refills: 4
citalopram 20 mg (1 tablet as directed) Qty: 90, Refills: 3

SOCIAL HISTORY
Smoking Status entered on 10/26/2011 1:33:45 PM recorded as Former smoker
ALCOHOL USE: moderate
DRUG USE:none
GAMBLING: none
MARITAL STATUS: married 16 yrs
OCCUPATION: court security office
TOBACCO USE: quit 2009

PAST MEDICAL HISTORY
725 Polymyalgia rheumatica
172.9 Melanoma of skin, site unspecified
604.99 Other orchitis, epididymitis, and epididymo-orchitis, without mention of abscess
HOSPITALIZATIONS:colitis
SURGICAL HISTORY: L4 disc with staph infection, L orchiectomy, appy, T&A, phobo
IMMUNIZATIONS:
INFLUENZA-
PNEUMOVAX-
Tdap-
SHINGLES-
HPV-
Hep A-
Hep B-
PPD-
C-scope- 2008
Mammo-
Dexa -
PSA-1996
Pap-
CXR - 1998

FAMILY HISTORY
Family History:
Htn: none
CAD: none
DM: none
Cancer: Sis - skin, Bro - lung, PU - lung
ETOH/ Drug Abuse: none
Generated by Cooperable Health Records

VITALS
DATE: 05/29/2012 TIME: 08:30:00 WT: 212 HR: 88 RESP: 16 BP (SYS/DIA): (L) 130/72

C/C OR REASON FOR VISIT
lab results
blood pressure

HISTORY OF PRESENT ILLNESS
» LAB RESULTS
follow up on lab results
» BLOOD PRESSURE
no longer taking toprol XL, has not had med about 5 days ago, unable to get a refill.
PT also states he has had abdominal pain mid and epigastic that radiated around the back and up in between the shoulder blades. Wife is with pt today and she said she was worried about enough, (it has happend 3-5 times) that she called family friend Dr Les Smith. he suggested Dan get checked for pancreatitis and that he would call another MD Dr Gray. They are waiting to hear back from his office.
Dan states that this occured over the last 4-5 weeks he throw up "food' not any coffe grounds. He states years ago he had a peptic ulcer. he also states he has been drinking 1 martinin/day adn up to 4-5 martinins on weekends. He doesnot think he has a problem with alchohol. His wife also thinks he doesnot. although he does acknowledge ethol use was a problem in the past. He no long er smokes cigs (quit 3 yrs ago)..
He notes no bowel change he thiks the weight gain is an error in weighing him last time.
He is not nauseated today. has no pain He sometimes takes exedrin or motrin (rare) and takes 2 tabs 81 mg of ASA per day (good for your heart)/

PHYSICAL EXAM
» LAB RESULTS
GENERAL APPEARANCE: alert, no acute distress.
NECK: carotids normal, normal examination, supple, thyroid normal.
CARDIOVASCULAR: no friction rub, no gallop, no murmer, normal heart sounds, pulses normal, regular rate and rhythm.
RESPIRATORY: breath sounds normal, no respiratory distress.
ABDOMEN: Obese soft with mild \ epigastic TTP There is no + Murphys sign. There are no masses.
BUN 1.28 GFR 54 Cholestrol 182 LDI 104

DIAGNOSIS

Alcohol abuse, unspecified	305.00
Vomiting alone	787.03
Abdominal tenderness, epigastric	789.66
Osteoarthrosis, unspecified whether generalized or localized, hand	715.94
Essential hypertension, benign	401.1

PLAN

Received
OCT 15 2012
CCMSI-Reno

ACADIA MEDICAL GROUP
Acadia Medical Group
900 Ryland Street
Reno, NV 89502
Phone: 775-786-3555
Fax: 775-786-3088

DEMARANVILLE, DANIEL E
PO BOX 261
VERDI, NV 89439
Born 10/04/1934 (77 years)
775-345-6530

Visit Date	Visit With	Visit Description
5/29/2012	Lydon APN, Kathleen (3)	Regular

Psych: none
Endo: none
Renal: none
Pulm: none
Herna: none
Arth: M. Sls - knee
GI: none
Neuro: none

VISIT CODE
ESTABLISHED PATIENT M. COMPLEXITY (99214)

RX PRESCRIPTIONS
Toprol XL 25 mg (1 tablet DAILY) Qty: 90, Refills: 0

LAB
ALPHA / COMBO TESTS: *CMP
ALPHA / COMBO TESTS: AMYLASE (82150)
ALPHA / COMBO TESTS: LIPASE (83690)
ALPHA / COMBO TESTS: H. PYLORI BREATH TEST

RADIOLOGY
GU & GI UGI (air contract is routine)

REFERRALS
Gastroenterology

E-SIGNATURES
Authenticated By: Lydon APN, Kathleen @ 5/29/2012 6:02 PM

ADDENDUM
===Addendum 5/29/2012 8:37 PM ==========
===Hastings MD, Dulynn =======
Reviewed

Received
OCT 15 2012
CCMSI-Reno

Reno Diagnostic Centers
590 Eureka Avenue • Reno, Nevada 89512
Phone (775) 323-5083 Fax (775) 323-2193

****
Reprinted from Electronic Medical Record - Created on 06/01/12 15:51:39
Patient: DEMARANVILLE, DANIEL MR No.: 160912 DOB: 10/04/1934
****

PATIENT NAME: Demaranville, Daniel E **MRN: 160912**
DOB: 10/04/1934 **AGE/SEX: 77/M**
REFERRING PHYSICIAN: LYDON, KATIE APN (775)786-3555

EXAM DATE: 06/01/2012
ACCESSION: 892148
EXAM: FLUORO- FLUORO_EU-RF - UGI W KUB W Air
EXAM LOCATION: RDC

CLINICAL INDICATION: Epigastric pain, vomiting.

TECHNIQUE: Routine double contrast barium swallow and upper GI series.

COMPARISON: None.

FINDINGS:
The patient swallowed barium without difficulty. Scattered tertiary contractions were noted. Esophageal motility was otherwise normal. No fixed esophageal lesion or mucosal irregularity was seen. There is a small sliding hiatal hernia. Marked spontaneous gastroesophageal reflux into the upper thoracic esophagus occurred with rolling. A 13 mm tablet passed easily through the GE junction.

The stomach distended well with air and contrast. No ulceration, fold thickening, or mass was seen. The duodenal bulb and C-loop were normal in appearance.

IMPRESSION:
1. Small sliding hiatal hernia.
2. Marked spontaneous gastroesophageal reflux.
3. No evidence of esophagitis or a gastric ulcer.

CC:

Read and Electronically Signed by: Robert W. Hastings, MD
Reviewed By: Robert W. Hastings, MD
Date/Time Dictated: 06/01/2012 15:51:39 PM

Electronically signed by Robert W. Hastings, MD 6/1/2012 15:6:39

Received
OCT 15 2012
CCMSP-Reno

LabCorp

Multiple Performing Labs
See End of Report for Details

DEMARANVILLE, DANIEL
PO BOX 261
Verdi, NV 89439-
DOB: 1934-10-04
Gender: Male
Patient Account # (at Lab): 27896221
Patient ID (at Lab): 3081375

Group Number
15382020860

Comp. Metabolic Panel (14) (L:322000)

Report Date:	Observation Date:	Specimin Source:	Specimin Received Date:
2012-06-05 17:05	2012-06-01 09:51		2012-06-01 17:46

Test Name	Test Value	Unit of Measure	Range	Flag	Lab
Glucose, Serum (L:001032)	92	mg/dL	65-99		01
BUN (L:001040)	21	mg/dL	8-27		01
Creatinine, Serum (L:001370)	1.11	mg/dL	0.76-1.27		01
eGFR If NonAfricn Am (L:100791)	64	mL/min/1.73	>59		01
eGFR If Africn Am (L:100797)	74	mL/min/1.73	>59		01
BUN/Creatinine Ratio (L:011577)	19		10-22		01
Sodium, Serum (L:001198)	142	mmol/L	134-144		01
Potassium, Serum (L:001180)	4.4	mmol/L	3.5-5.2		01
Chloride, Serum (L:001206)	101	mmol/L	97-108		01
Carbon Dioxide, Total (L:001578)	28	mmol/L	20-32		01
Calcium, Serum (L:001016)	9.1	mg/dL	8.6-10.2		01
Protein, Total, Serum (L:001073)	6.1	g/dL	6.0-8.5		01
Albumin, Serum (L:001081)	4.2	g/dL	3.5-4.8		01
Globulin, Total (L:012039)	1.9	g/dL	1.5-4.5		01
A/G Ratio (L:012047)	2.2		1.1-2.5		01
Bilirubin, Total (L:001099)	0.5	mg/dL	0.0-1.2		01
Alkaline Phosphatase, S (L:001107)	42	IU/L	25-160		01
AST (SGOT) (L:001123)	25	IU/L	0-40		01
ALT (SGPT) (L:001545)	22	IU/L	0-55		01

Amylase, Serum (L:001396)

Report Date:	Observation Date:	Specimin Source:	Specimin Received Date:
2012-06-05 17:05	2012-06-01 09:51		2012-06-01 17:46

Test Name	Test Value	Unit of Measure	Range	Flag	Lab
Amylase, Serum (L:001396)	76	U/L	31-124		01

Lipase, Serum (L:001404)

Report Date:	Observation Date:	Specimin Source:	Specimin Received Date:
2012-06-05 17:05	2012-06-01 09:51		2012-06-01 17:46

Test Name	Test Value	Unit of Measure	Range	Flag	Lab
Lipase, Serum (L:001404)	25	U/L	0-59		01

Received
OCT 15 2012
Claims Mgmt

H. pylori Breath Test (L:180836)

Report Date:	Observation Date:	Specimin Source:	Specimin Received Date:

LabCorp

Multiple Performing Labs
See End of Report for Details

DEMARANVILLE, DANIEL
PO BOX 261
Verdi, NV 89439-
DOB: 1934-10-04
Gender: Male
Patient Account # (at Lab): 27896221
Patient ID (at Lab): 3081375

2012-06-05 17:05	2012-06-01 09:51		2012-06-01 17:46	
Test Name	Test Value	Unit of Measure	Range	Flag	Lab
H. pylori Breath Test (L:180836)	Negative		Negative		02

Performing Labs Index

01 LabCorp Phoenix 3930 E Watkins Suite 300 Phoenix, AZ 850347251 602.454.6000
Director: Frank, Ryan PhD

02 LabCorp Burlington 1447 York Court Burlington, NC 272153361 800.762.4344
Director: William F, Hancock MD

Clinical Test Ordered By K LYDON (1710087341)

Reviewed by: Lydon APN, Kathleen on 6/5/2012

Received
OCT 15 2012
CCMSP-Reno

Gastroenterology Consultants, Ltd

Victor Chen M.D., Hong Gao M.D., John Gray M.D., Juan Gregory M.D.,
Timothy Halterman M.D., Philip Harper M.D., Clark Harrison M.D., Jan Kamler M.D.,
Loth Lieberstein M.D., Christ Matteoni M.D., John McAlee M.D., James Nachiondo M.D.,
Daniel Nason M.D., Eric Oegard M.D., Jonathan Pezanoski M.D.,
A.N. Reddy M.D., Craig Sands M.D., Michael Solinger M.D.,
Christopher Bartlett PAC, Paul Johns PAC, Julie Thomas PAC, Sidney Warner MS,RD,PAC

GI Consultants - Reno South Clinic
10519 Professional Circle Reno, NV 89521
P: 7758524848 F: 7758505783

Daniel E DeMaranville H:Home: (775) 345-6530 W: Office: (775) 233-4102
Male **DOB:**10/04/1934 186145 **Ins:**Ins: Medicare Palmetto GBA NonConsult

08/07/2012 - Procedures: EGD Report
Provider: John F Gray MD
Location of Care: South Meadows Endoscopy Center
This document contains confidential information

UPPER ENDOSCOPY REPORT

June 7, 2012
Procedure(s): Panendoscopy (EGD) and biopsy
Indications:
Symptoms of abdominal pain, nausea and vomiting.

The patient's history was reviewed and a physical examination was performed immediately prior to the procedure. The patient was deemed ASA class II and considered an appropriate candidate for the procedure. The risks, benefits and alternatives were discussed with the patient and informed consent obtained. Moderate conscious sedation was administered under the direction of the endoscopist while patient was monitored with continuous pulse oximetry, cardiac monitor, and serial vital signs. **Procedure Medications given:** Midazolam 4 mg IV and Fentanyl 50 mcg IV.

Procedure Description: The scope was inserted via the mouth and extended to the duodenum. The scope was retroflexed within the stomach to view the fundus and cardia. The patient's tolerance of the procedure was good. ***A complete examination was obtained.***

Esophageal Findings
Normal esophagus

Gastric Findings
Mucosal Abnormality

Located in the body, antrum. Severity is moderate. The mucosa was notable for erythema, erosions and ulceration. The mucosa was sampled with cold biopsy forceps. (Specimen A). Multiple superficial gastric ulcers and erosions.

Duodenal Findings
Normal duodenum

Adverse Events: None.

Received
OCT 15 2012
CCMSI-Reno

159

328 298

Gastroenterology Consultants, Ltd

Victor Chen M.D., Hong Gao M.D., John Gray M.D., Juan Gregory M.D.,
Timothy Heitzmen M.D., Phillip Harper M.D., Clark Harrison M.D., Jan Kamler M.D.,
Loth Lieberstein M.D., Christi Matteoni M.D., John McAfee M.D., James Nachlonde M.D.,
Daniel Nason M.D., Eric Oegard M.D., Jonathan Pazaniosk M.D.,
A.N. Reddy M.D., Craig Sande M.D., Michael Sollinger M.D.,
Christopher Bartlett PAC, Paul Johns PAC, Julie Thomas PAC, Sidney Warner MS RD,PAC

GI Consultants - Reno South Clinic
10619 Professional Circle Reno, NV 89521
P: 7758524848 F: 7758505783

Daniel E DeMaranville H:Home: (775) 345-6530 W: Office: (775) 233-4102
Male DOB:10/04/1934 186145 Ins:Ins: Medicare Palmetto GBA NonConsult

Impression

1. Moderate ulcerative gastritis, biopsied

Plan

Omeprazole 20 qd
Consider switching to non-NSAID pain reliever
Office visit 4 wks
Abd ultrasound

cc: Katie Lydon APN

Electronically signed by John F Gray MD on 08/07/2012 at 12:04 PM

Received
OCT 15 2012
CCHSI-Reno

160

329 299

Gastroenterology Consultants
Pathology Laboratory
880 Nyland Street, Reno, NV 89502
775.329.4600

Case Number: B2012-003839

Physician: John Gray MD, MD

Patient Name: DeMaranville, Daniel E

DOB: 10 04 1934

Sex: M

Collection Date: 06 07 2012

Medical Record Number: 186145

Received Date: 06 07 2012

Source
Gastric

Diagnosis
Mild chronic gastritis with focal activity; negative for intestinal metaplasia, dysplasia, or malignancy. Negative for H. pylori by special stain.
(gh)

Gross
Received in formalin, labeled with the patient's name, date of birth, and "gastric biopsy," are two fragments of tan-brown, soft tissue, measuring 0.6 x 0.4 x 0.2 cm in aggregate. Entirely submitted in a single cassette.

Microscopic
Sections demonstrate gastric mucosa with mild chronic inflammation, focal acute inflammation, and reactive epithelial changes. There is no evidence of intestinal metaplasia, dysplasia, or malignancy. A Diff-quik stain is negative for H. pylori. Positive control is appropriate.

Electronic Signature

Grant M. Hayashi MD, Pathologist
(Case signed 06 08 2012)

Received
OCT 15 2012
CCMST-Reno

Duplicate copy

161

330 300

Gastroenterology Consultants, Ltd

Victor Chen M.D., Hong Gao M.D., John Gray M.D., Juan Gregory M.D.,
Timothy Halterman M.D., Phillip Harper M.D.,Clark Harrison M.D., Jan Kamler M.D.,
Loth Lieberstein M.D., Christi Matteoni M.D., John McAfee M.D.,James Nachiondo M.D.,
Daniel Nason M.D., Eric Osgard M.D., Jonathan Pezanoski M.D.,
A.N. Reddy M.D., Craig Sande M.D., Michael Solinger M.D.,
Christopher Bartlett PAC, Paul Johns PAC, Julie Thomas PAC, Sidney Warner MS,RD,PAC

GI Consultants - Reno South Clinic
10619 Professional Circle Reno, NV 89521
P: 7758524848 F: 7758505763

Daniel E DeMaranville H:Home: (775) 345-6530 W: Office: (775) 233-4102
Male DOB:10/04/1934 186145 Ins: Medicare Palmetto GBA NonConsult

07/06/2012 - Office Visit: Gastritis
Provider: John F Gray MD
Location of Care: GI Consultants - Reno South Clinic
This document contains confidential information

Reason for Visit: routine follow-up **Chief Complaint:** abdominal pain

History of Present Illness:

The patient is a 77-year-old male with history of hypertension, alcohol abuse and osteoarthrosis who is returning for follow-up regarding a 6-week history of abdominal pain.

EGD revealed moderate ulcerative gastritis. Biopsies were negative for H. pylori. He has been taking omeprazole and his nausea has resolved. His abdominal pain is 30% improved.

He continues to have upper abdominal pain primarily aggravated by movement and it radiates into his back. There may also be a postprandial component but he is uncertain.

Abdominal ultrasound revealed an echogenic liver and a small septated liver cyst.

Past Medical History

Hypertension

GI Procedure History

– egd 6/12: Moderate ulcerative gastritis, biopsied (neg)

Surgical History

back x 6
appendix
hernia

Received
OCT 15 2012
CCMSI-Reno

ALLERGIES
PENICILLIN (Critical)

MEDICATIONS
OMEPRAZOLE 20 MG CPDR (OMEPRAZOLE) 1 TAB PO daily 30 minutes before a meal
VIAGRA 100 MG TABS (SILDENAFIL CITRATE) as needed (outside provider)
ASPIRIN 81 MG TABS (ASPIRIN) one daily (outside provider)
METOPROLOL SUCCINATE 25 MG XR24H-TAB (METOPROLOL SUCCINATE) one by mouth daily (outside provider)
DOXAZOSIN MESYLATE 2 MG TABS (DOXAZOSIN MESYLATE) one by mouth daily (outside

Gastroenterology Consultants, Ltd

Victor Chen M.D., Hong Gao M.D., John Gray M.D., Juan Gregory M.D.,
Timothy Halterman M.D., Philip Harper M.D.,Clark Harrison M.D., Jan Kamler M.D.,
Loth Lieberstein M.D., Christi Matteoni M.D., John McAfee M.D.,James Nachiondo M.D.,
Daniel Nason M.D., Eric Osgard M.D., Jonathan Pezanoski M.D.,
A.N. Reddy M.D., Craig Sande M.D., Michael Solinger M.D.,
Christopher Bartlett PAC, Paul Johns PAC, Julie Thomas PAC, Sidney Warner MS,RD,PAC

GI Consultants - Reno South Clinic
10619 Professional Circle Reno, NV 89521
P: 7758524848 F: 7758505763

Daniel E DeMaranville H: Home: (775) 345-8530 W: Office: (775) 233-4102
Male DOB:10/04/1934 186145 Ins: Ins: Medicare Palmetto GBA NonConsult

provider)
CELEXA 20 MG TABS (CITALOPRAM HYDROBROMIDE) one by mouth daily (outside provider)

Social History

Marital Status: married
Exercise type: walking frequency: occasionally days per week: 1-2 /wk
Caffeine use, type: coffee **number daily:** 3-5 /day

Alcohol Use
How often do you drink: occasionally
type: wine and liquor **days per week:** 7
drinks per occasion: 1-2 **frequency of > 5 drinks:** never

Tobacco Use
Tobacco use: unknown if ever smoked **Packs per day:** 1-2 **Years smoked:** >10
Cigars/pipes per wk: 1-2
Smokeless/chew per wk: 0

Review of Systems

Gastrointestinal: Complains of heartburn,abdominal pain,nausea,vomiting,flatulence.
General: Complains of fatigue, weight gainWeight loss 8 lbs in recent weeks.
Cardiovascular: Complains of palpitations.
Respiratory: Complains of shortness of breath.
Bone and Joint: Complains of arthritis,back pain,joint pain.
The remainder of the complete review of systems was negative.

Vital Signs

P 78 **PR** Regular **BP** 110/68 **Wt** 206 **Last Ht** 71 (06/06/2012) **Body Mass Index:** 28.84

Physical Examination

Received
OCT 15 2012
CCMSI-Reno

Medicare Colorectal Cancer PQRI Questionnaire Completed

Impression and Recommendations:

1. Abdominal pain, nausea and vomiting at least in part due to ulcerative gastritis. He is having some residual pain that radiates into his back aggravated by movement and this indeed may be referred pain from his back.
2. Moderate ulcerative gastritis secondary to NSAIDs
3. Septated liver cyst. This will require follow
4. Hiatal hernia with marked reflux on upper GI series

Gastroenterology Consultants, Ltd

Victor Chen M.D., Hong Gao M.D., John Gray M.D., Juan Gregory M.D.,
Timothy Halterman M.D., Philip Harper M.D.,Clark Harrison M.D., Jan Kamler M.D.,
Loth Liebersten M.D., Christi Matteoni M.D., John McAfee M.D.,James Nachiondo M.D.,
Daniel Nason M.D., Eric Osgard M.D., Jonathan Pszanoski M.D.,
A.N. Reddy M.D., Craig Sands M.D., Michael Schinger M.D.,
Christopher Bartlett PAC, Paul Johns PAC, Julie Thomas PAC, Sidney Warner MS,BD,PAC

GI Consultants - Reno South Clinic
10619 Professional Circle Reno, NV 89521
P: 7758524848 F: 7758505763

Daniel E DeMaranville H:Home: (775) 345-6530 W: Office: (775) 233-4102
Male DOB:10/04/1934 186145 Ins: Ins: Medicare Palmetto GBA NonConsult

5. History alcohol abuse which has moderated slightly
6. Chronic osteoarthrosis on chronic NSAIDs
7. Patient needs colon cancer screening
8. History 8 lb weight loss
9. History hypertension

I will arrange for AFP, CEA, CA-19-9, CT scan of abdomen and contact him with the results and recommendations. If these are all normal I will arrange for HIDA/CCK.

This note was generated using voice recognition software which has a small chance of producing errors of grammar and possibly content. I have made every reasonable attempt to find and correct any obvious errors, but expect that some may not be found prior to finalization of this note. .
cc: Katie Lydon APN

Electronically signed by John F Gray MD on 07/06/2012 at 2:53 PM

Received
OCT 16 2012
CCMRT-Reno

164

Gastroenterology Consultants, Ltd

Victor Chen M.D., Hong Gao M.D., John Gray M.D., Juan Gregory M.D.,
Timothy Halterman M.D., Philip Harper M.D., Clark Harrison M.D., Jan Kamler M.D.,
Loth Lieberstein M.D., Christo Madeoni M.D., John McAfee M.D., James Nachiondo M.D.,
Daniel Nason M.D., Eric Osgard M.D., Jonathan Pazanoski M.D.,
A.N. Reddy M.D., Craig Sande M.D., Michael Sollinger M.D.,
Christopher Bartlett PAC, Paul Johns PAC, Julie Thomas PAC, Sidney Werner MS, RD, PAC

GI Consultants - Reno North Clinic
680 Ryland Reno, NV 89502
P: 7753294800 F: 7753294982

Daniel E DeMaranville H:Home: (775) 345-6530 W: Office: (775) 233-4102
Male DOB:10/04/1934 186145 Ins:Ins: Medicare Palmetto GBA NonConsult

07/06/2012 - Lab Report: CEA, AFP, CA 19-9, BUN, Creatinine,Lipase: nml
Provider: John F Gray MD
Location of Care: Not a Location of Care

Patient: DANIEL DEMARANVILLE
ID: 1100 18813401180
Note: All result statuses are Final unless otherwise noted.
Patient Note: A courtesy copy of this report has been sent to
Patient Note: 775-333-2776.
Patient Note: PATIENT NOT FASTING

Tests: (1) CEA (002139)

CEA *1	2.3 ng/mL	0.0-4.7

Roche ECLIA methodology — Nonsmokers <3.9; Smokers <5.6

Tests: (2) AFP, Serum, Tumor Marker (002253)

AFP, Serum, Tumor Marker *2	5.2 ng/mL	0.0-8.3

Roche ECLIA methodology

Tests: (3) CA 19-9 (002261)

! CA 19-9 *3	8 U/mL	0-35

Roche ECLIA methodology

Tests: (4) BUN (001040)

BUN *4	23 mg/dL	8-27

Tests: (5) Creatinine, Serum (001370)

Creatinine, Serum *5	1.27 mg/dL	0.76-1.27
! eGFR If NonAfricn Am [L] *6	54 mL/min/1.73	>59
! eGFR If Africn Am *7	63 mL/min/1.73	>59

Tests: (6) Lipase, Serum (001404)

Lipase, Serum *8	24 U/L	0-59

Performed At: PD, LabCorp Phoenix
3930 E Watkins Suite 300 Phoenix, AZ 850347251

Received
OCT 15 2012
CCMSP-Reno

Gastroenterology Consultants, Ltd

Victor Chen M.D., Hong Gao M.D., John Gray M.D., Juan Gregory M.D.,
Timothy Halterman M.D., Phillip Harper M.D., Clark Harrison M.D., Jan Kemler M.D.,
Lori Lieberstein M.D., Christi Marteoni M.D., John McAfee M.D., James Nachlonde M.D.,
Daniel Nason M.D., Eric Osgard M.D., Jonathan Pezanoski M.D.,
A.N. Reddy M.D., Craig Sande M.D., Michael Sollinger M.D.,
Christopher Bartlett PAC, Paul Johns PAC, Julie Thomas PAC, Sidney Warner MS,RD,PAC

GI Consultants - Reno North Clinic
880 Ryland Reno, NV 89502
P: 7753294800 F: 7753294992

Daniel E DeMaranville H:Home: (775) 345-6530 W: Office: (775) 233-4102
Male DOB:10/04/1934 -186145 Ins:Ins: Medicare Palmetto GBA NonConsult

Frank Ryan PhD Phone: 6024548000

Note: An exclamation mark (!) indicates a result that was not dispersed into the flowsheet.
Document Creation Date: 07/09/2012 11:26 AM

---

(1) Order result status: Final
Collection or observation date-time: 07/06/2012 15:55
Requested date-time:
Receipt date-time: 07/06/2012 18:03
Reported date-time: 07/07/2012 10:05
Referring Physician:
Ordering Physician: J GRAY (1982680765)
Specimen Source:
Source: 1100
Filler Order Number: 18813401180 LAB
Lab site: 18813401180
Producer ID *1:PD

(2) Order result status: Final
Collection or observation date-time: 07/06/2012 15:55
Requested date-time:
Receipt date-time: 07/06/2012 18:03
Reported date-time: 07/07/2012 10:05
Referring Physician:
Ordering Physician: J GRAY (1982680765)
Specimen Source:
Source: 1100
Filler Order Number: 18813401180 LAB
Lab site: 18813401180
Producer ID *2:PD

(3) Order result status: Final
Collection or observation date-time: 07/06/2012 15:55
Requested date-time:
Receipt date-time: 07/06/2012 18:03
Reported date-time: 07/07/2012 10:05
Referring Physician:
Ordering Physician: J GRAY (1982680765)
Specimen Source:
Source: 1100
Filler Order Number: 18813401180 LAB
Lab site: 18813401180
Producer ID *3:PD

(4) Order result status: Final
Collection or observation date-time: 07/06/2012 15:55
Requested date-time:

Received
OCT 16 2012
CCMSI-Reno

166

Gastroenterology Consultants, Ltd

Victor Chan M.D., Hong Gao M.D., John Gray M.D., Juan Gregory M.D.,
Timothy Halterman M.D., Philip Harper M.D., Clark Harrison M.D., Jan Kamler M.D.,
Loth Lieberstein M.D., Christi Medeiros M.D., John McAfee M.D., James Nachiondo M.D.,
Daniel Nason M.D., Eric Osgard M.D., Jonathan Pezanoski M.D.,
A.N. Reddy M.D., Craig Sande M.D., Michael Solinger M.D.,
Christopher Bartlett PAC, Paul Johns PAC, Julie Thomas PAC, Sidney Warner MS, RD, PAC

GI Consultants - Reno North Clinic
880 Ryland Reno, NV 89502
P: 7753294600 F: 7753294692

Daniel E DeMaranville H:Home: (775) 345-6530 W: Office: (775) 233-4102
Male DOB:10/04/1934 186145 Ins:Ins: Medicare Palmetto GBA NonConsult

Receipt date-time: 07/06/2012 18:03
Reported date-time: 07/07/2012 10:05
Referring Physician:
Ordering Physician: J GRAY (1982680765)
Specimen Source:
Source: 1100
Filler Order Number: 18813401180 LAB
Lab site: 18813401180
Producer ID *4:PD

(5) Order result status: Final
Collection or observation date-time: 07/06/2012 15:55
Requested date-time:
Receipt date-time: 07/06/2012 18:03
Reported date-time: 07/07/2012 10:05
Referring Physician:
Ordering Physician: J GRAY (1982680765)
Specimen Source:
Source: 1100
Filler Order Number: 18813401180 LAB
Lab site: 18813401180
Producer ID *5:PD
Producer ID *6:PD
Producer ID *7:PD

(6) Order result status: Final
Collection or observation date-time: 07/06/2012 15:55
Requested date-time:
Receipt date-time: 07/06/2012 18:03
Reported date-time: 07/07/2012 10:05
Referring Physician:
Ordering Physician: J GRAY (1982680765)
Specimen Source:
Source: 1100
Filler Order Number: 18813401180 LAB
Lab site: 18813401180
Producer ID *8:PD

The following results were not dispersed to the flowsheet:

CA 19-9, 8 U/mL, (F)
eGFR If NonAfricn Am, 54 mL/min/1.73, (F)
eGFR If Africn Am, 63 mL/min/1.73, (F)

Electronically signed by John F Gray MD on 07/09/2012 at 11:39 AM

Received
OCT 15 2012
CCMSI-Reno

167

Gastroenterology Consultants, Ltd

Victor Chen M.D., Hong Gao M.D., John Gray M.D., Juan Gregory M.D.,
Timothy Halbenman M.D., Phillip Harper M.D., Clark Harrison M.D., Jan Kamler M.D.,
Lotti Lieberstein M.D., Christi Matteoni M.D., John McAlee M.D., James Nachlonde M.D.,
Daniel Nason M.D., Eric Oagard M.D., Jonathan Pazanoski M.D.,
A.N. Reddy M.D., Craig Sande M.D., Michael Sollinger M.D.,
Christopher Bartlett PAC, Paul Johns PAC, Julie Thomas PAC, Sidney Warner MS,RD,PAC

GI Consultants - Reno North Clinic
860 Ryland Reno, NV 89502
P: 7753294800 F: 7753294992

Daniel E DeMaranville H:Home: (775) 345-6530 **W:** Office: (775) 233-4102
Male **DOB:**10/04/1934 186145 **Ins:**Ins: Medicare Palmetto GBA NonConsult

Received
OCT 15 2012
CCMSI-Reno

168

Reno Diagnostic Centers
590 Eureka Avenue • Reno, Nevada 89512
Phone (775) 323-5083 Fax (775) 323-2193

****
Reprinted from Electronic Medical Record - Created on 07/23/12 11:52:54
Patient: DEMARANVILLE, DANIEL MR No.: 160912 DOB: 10/04/1934
****

PATIENT NAME: Demaranville, Daniel E
DOB: 10/04/1934
REFERRING PHYSICIAN: GRAY, JOHN (775)852-4848

MRN: 160912
AGE/SEX: 77/M

EXAM DATE: 07/20/2012
ACCESSION: 905032
EXAM: MRI_SR- MRI_SR-MR - Abdomen W andW O contras
EXAM LOCATION: RDC

CLINICAL INDICATION: Hepatic cyst. Abdominal pain, vomiting after eating, history of cirrhosis.

TECHNIQUE: Routine multiplanar imaging of the abdomen without and with contrast, performed on the Siemens Espree Wide Bore 1.5T system with 860 images obtained.

COMPARISON: Ultrasound from 6/8/2012

FINDINGS:
There is a multiloculated cystic lesion consistent with biliary hamartoma (cyst) at the junction of the medial and lateral segments of the left lobe near the dome measuring 2.6 cm in diameter (axial series 4 image 9). There is a tiny adjacent cyst along its posterior margin. Postcontrast, there is the suggestion of faint rim and septal enhancement. No nodularity or solid component is seen. There is a subcentimeter cyst in the posterior right lobe (axial series 2 image 14) and a small cyst in the lateral segment of the left lobe of the dome (axial series 4 image 12).

The gallbladder is unremarkable. There is no intra- or extrahepatic biliary ductal dilatation. The common hepatic duct measures up to 3 mm. There is no cholelithiasis or choledocholithiasis.

The pancreas is unremarkable in appearance. The pancreatic duct measures less than 3 mm. No filling defects are present in the pancreatic duct.

There is an exophytic cyst arising from the posterior aspect of the left kidney. Kidneys are otherwise unremarkable. Adrenal glands are within normal limits. There is no retroperitoneal adenopathy or free fluid in the upper abdomen.

IMPRESSION:
Hepatic cysts. No followup is required.

Received
OCT 15 2012
CCMSI-Reno

DEMARANVILLE, DANIEL MRN: 160912 DOB: 10/04/1934

CC:

Read and Electronically Signed by: Robert W. Hastings, MD
Reviewed By: Robert W. Hastings, MD
Date/Time Dictated: 07/23/2012 11:52:53 AM

Electronically signed by Robert W. Hastings, MD 7/23/2012 11:7:54

Received
OCT 15 2012
CCHRI Reno

170

Reno Diagnostic Centers
590 Eureka Avenue • Reno, Nevada 89512
Phone (775) 323-5083 Fax (775) 323-2193

****
Reprinted from Electronic Medical Record - Created on 07/26/12 17:09:40
Patient: DEMARANVILLE, DANIEL MR No.: 160912 DOB: 10/04/1934
****

PATIENT NAME: Demaranville, Daniel E **MRN: 160912**
DOB: 10/04/1934 **AGE/SEX: 77/M**
REFERRING PHYSICIAN: GRAY, JOHN (775)852-4848

EXAM DATE: 07/26/2012
ACCESSION: 909299
EXAM: NUC MED- NUC_EU-NM - HIDA Ductal Img W OorW CCK
EXAM LOCATION: RDC

CLINICAL INDICATION: Intermittent abdominal pain, worse after eating.

RADIOPHARMACEUTICAL: 6.3 mCi Tc99m Choletec.

COMPARISON: Ultrasound from 6/8/2012.

PROCEDURE: Following the intravenous administration of Tc99m Choletec, sequential images of the liver, gallbladder, and small bowel were obtained for 60 minutes.

1.87 ug of CCK was then infused intravenously over 30 minutes. Images were acquired during the infusion and for an additional 10 minutes after infusion. The gallbladder ejection fraction was calculated using region-of-interest analysis at 10, 20, and 30 minutes. The patient experienced abdominal pressure during the CCK infusion, different from the previous symptoms.

FINDINGS:
Phase 1 (pre CCK): There is normal hepatic extraction and concentration of Choletec. The gallbladder is visualized at 12 minutes and the small bowel is visualized at 48 minutes.

Phase 2 (post CCK): Visually, there is poor gallbladder contraction. Ejection fraction was estimated at 22%. There was no appreciable enterogastric reflux.

IMPRESSION:
1. No evidence of cystic or common duct obstruction.
2. Impaired gallbladder contraction, with an ejection fraction of 22% While the range of normal for gallbladder ejection fraction is broad, patients with gallbladder dyskinesia typically have an ejection fraction less than 35%.

Received
OCT 15 2012
CCMSI-Reno

171

DEMARANVILLE, DANIEL MRN: 160912 DOB: 10/04/1934

CC:

Read and Electronically Signed by: Robert W. Hastings, MD
Reviewed By: Robert W. Hastings, MD
Date/Time Dictated: 07/26/2012 17:09:39 PM

Electronically signed by Robert W. Hastings, MD 7/26/2012 17:7:41

Received
OCT 16 2012
CCMSI-Reno

Gastroenterology Consultants, Ltd

Victor Chen M.D., Hong Gao M.D., John Gray M.D., Juan Gregory M.D.,
Timothy Halterman M.D., Philip Harper M.D.,Clark Harrison M.D., Jan Kanter M.D.,
Loth Liebenstein M.D., Christi Matteoni M.D., John McAfee M.D.,James Nachiondo M.D.,
Daniel Nasen M.D., Eric Osgard M.D., Jonathan Pezanoski M.D.,
A.N. Reddy M.D., Craig Sande M.D., Michael Solinger M.D.,
Christopher Bartlett PAC, Paul Johns PAC, Julie Thomas PAC, Sidney Warner MS,RD,PAC

GI Consultants - Reno South Clinic
10519 Professional Circle Reno, NV 89521
P: 7758524848 F: 7758505763

Daniel E DeMaranville H:Home: (775) 345-6530 W: Office: (775) 233-4102
Male **DOB:**10/04/1934 186145 Ins:Ins: Medicare Palmetto GBA NonConsult

08/01/2012 - Office Visit: Abd pain
Provider: John F Gray MD
Location of Care: GI Consultants - Reno South Clinic
This document contains confidential information

Reason for Visit: routine follow-up **Chief Complaint:** abdominal pain and liver cyst

History of Present Illness:

The patient is a 77-year-old male with history of hypertension, alcohol abuse and osteoarthrosis who is returning for follow-up regarding a 6-week history of abdominal pain and a liver cyst.

MRI of the liver showed that the liver cyst is a biliary hamartoma. No further follow-up is necessary.

HIDA scan showed a 22% ejection fraction and reproduced his pain.

CEA, CA-19-9, AFP were normal.

He continues to have frequent severe episodes of epigastric pain that are occasionally postprandial.

He now remembers that he had a negative colonoscopy with Dr. Fricke approximately 5 or 6 years ago.

Past Medical History

Hypertension
biliary dyskinesia,
biliary hamartomatous liver cyst
gastritis

GI Procedure History

-- colonoscopy ~ 2007 (Fricke): Nml
-- egd 6/12: Moderate ulcerative gastritis, biopsied (neg)

Surgical History

back x 6
appendix
hernia

Received
OCT 16 2012
CCMSI-Reno

173

342 312

Gastroenterology Consultants, Ltd

Victor Chen M.D., Hong Gao M.D., John Gray M.D., Juan Gregory M.D.,
Timothy Hatterman M.D., Philip Harper M.D.,Clark Harrison M.D., Jan Kamler M.D.,
Loth Lieberstein M.D., Christi Matteoni M.D., John McAfee M.D.,James Nachtondo M.D.,
Daniel Nason M.D., Eric Oegard M.D., Jonathan Pazanowski M.D.,
A.N. Reddy M.D., Craig Sande M.D., Michael Solinger M.D.,
Christopher Bartlett PAC, Paul Johns PAC, Julie Thomas PAC, Sidney Warner MS,RD,PAC

GI Consultants - Reno South Clinic
10619 Professional Circle Reno, NV 89521
P: 7758524848 F: 7758505763

Daniel E DeMaranville **H:**Home: (775) 345-6530 **W:** Office: (775) 233-4102
Male **DOB:**10/04/1934: 186145 **Ins:**Ins: Medicare Palmetto GBA NonConsult

ALLERGIES
PENICILLIN (Critical)

MEDICATIONS
HYOSCYAMINE SULFATE 0.125 MG SUBL (HYOSCYAMINE SULFATE) One tab SL BID PRN for pain
OMEPRAZOLE 20 MG CPDR (OMEPRAZOLE) 1 TAB PO daily 30 minutes before a meal
VIAGRA 100 MG TABS (SILDENAFIL CITRATE) as needed (outside provider)
ASPIRIN 81 MG TABS (ASPIRIN) one daily (outside provider)
METOPROLOL SUCCINATE 25 MG XR24H-TAB (METOPROLOL SUCCINATE) one by mouth daily (outside provider)
DOXAZOSIN MESYLATE 2 MG TABS (DOXAZOSIN MESYLATE) one by mouth daily (outside provider)
CELEXA 20 MG TABS (CITALOPRAM HYDROBROMIDE) one by mouth daily (outside provider)

Social History
Marital Status: married
Exercise type: walking frequency: occasionally days per week: 1-2 /wk
Caffeine use, type: coffee **number daily:** 3-5 /day

Alcohol Use
How often do you drink: occasionally
type: wine and liquor **days per week:** 7
drinks per occasion: 1-2 **frequency of > 5 drinks:** never

Tobacco Use
Tobacco use: unknown if ever smoked **Packs per day:** 1-2 **Years smoked:** >10
Cigars/pipes per wk: 1-2
Smokeless/chew per wk: 0

Review of Systems

Vital Signs
P 72 **BP** 114/76 **Wt** 199 **Last Ht** 71 (06/06/2012) **Body Mass Index:** 27.86

Physical Examination

Medicare Colorectal Cancer PQRI Questionnaire Completed

Received
OCT 15 2012
CCHSI-Reno

Gastroenterology Consultants, Ltd

Victor Chen M.D., Hong Gao M.D., John Gray M.D., Juan Gregory M.D.,
Timothy Hatterman M.D., Philip Harper M.D.,Clark Harrison M.D., Jan Kemler M.D.,
Loth Liebersten M.D., Christi Matteoni M.D., John McAfee M.D.,James Nachiondo M.D.,
Daniel Nason M.D., Eric Osgard M.D., Jonathan Pezanoski M.D.,
A.N. Reddy M.D., Craig Sande M.D., Michael Solinger M.D.,
Christopher Bartlett PAC, Paul Johns PAC, Julie Thomas PAC, Sidney Werner MS,RD,PAC

GI Consultants - Reno South Clinic
10619 Professional Circle Reno, NV 89521
P: 7758524848 F: 7758505763

Daniel E DeMaranville H: Home: (775) 345-6530 W: Office: (775) 233-4102
Male **DOB:** 10/04/1934 186145 **Ins:** Ins: Medicare Palmetto GBA NonConsult

Impression and Recommendations:

1. Biliary dyskinesia with intermittent abdominal pain.
2. Moderate ulcerative gastritis secondary to NSAIDs
3. Biliary hamartomatous cyst, no follow-up necessary
4. Hiatal hernia with marked reflux on upper GI series
5. History alcohol abuse which has moderated slightly
6. Chronic osteoarthrosis on chronic NSAIDs

I have discussed the case with Dr. Gomez who has kindly agreed to see the patient in surgical consultation tomorrow. I will obtain records from Dr. Fricke regarding details of his prior colonoscopy and provide the patient a reminder when his next screening is due. He will continue omeprazole.

This note was generated using voice recognition software which has a small chance of producing errors of grammar and possibly content. I have made every reasonable attempt to find and correct any obvious errors, but expect that some may not be found prior to finalization of this note.

9. History hypertension.
cc: Katie Lydon APN, Myron J Gomez, M.D.

Electronically signed by John F Gray MD on 08/01/2012 at 4:05 PM

Received
OCT 15 2012
CCHST Reno

175

314

History and Physical

Patient Name:	Daniel Demaranville	**Create Date:**	August 2, 2012
Patient ID:	148884		
Sex:	Male		
Birthdate:	October 4, 1934		

Chief Complaint

- "I have pain after I eat"

History Of Present Illness

The patient is a 77 year old White male seen in surgical consultation for John F. Gray MD and Kathleen E. Lydon APNP for biliary dyskinesia.

He states the current symptoms are pain, nausea with vomiting, constipation and reflux that have been present for 2+ months. He complains of a moderate degree of pain which has increased , and is localized to the RUQ , epigastric region, LUQ , sternum, and has radiation through to the back. The patient relates nausea and vomiting with eating. He denies fever, chills, diarrhea, and jaundice.

Diagnostic Studies:
Recently, all laboratory tests were within normal limits. The current radiology workup includes a Hepatobiliary Scan with CCK and MRI . CCK stimulation revealed an ejection fraction of 22 %. The MRI revealed hepatic cysts and was negative for cholelithiasis or choledocholithiasis.

Past Medical History

Disease Name	Date Onset	Notes
Alcohol dependence, continuous	--	--
Back Pain	--	--
Benign Prostatic Hypertrophy	--	--
Depressive Disorder	--	--
Gastritis	6/2012	moderate, ulcerative
Hiatal hernia	--	--
Hypertension	--	--
Left Inguinal Hernia	pre-teens	--
Liver cysts	--	septated
Osteoarthrosis	--	--

Past Surgical History

Procedure Name	Date	Notes
Appendectomy	childhood	--
Back surgery	1971-current	lumbar, x6
EGD	6/2012	--
Inguinal hernia repair, left	pre-teens	--
Tonsillectomy	childhood	--

Medication List

Name	Date Started	Instructions
citalopram Oral Tablet 20 mg		take 1 tablet (20 mg) by oral route once daily
doxazosin Oral Tablet 2 mg		take 1 tablet (2 mg) by oral route once daily
hyoscyamine sulfate Oral Tablet 0.125 mg		--
omeprazole Oral Capsule, Delayed Release(E.C.) 20 mg		take 1 capsule (20 mg) by oral route once daily before a meal
ranitidine HCl Oral Capsule 300 mg		take 1 capsule (300 mg) by oral route once daily at bedtime
Viagra Oral Tablet 100 mg		take 1 tablet (100 mg) by oral route once daily as needed approximately 1 hour before sexual activity

Received
OCT 15 2012
CCMSI-Reno

116

[Digital Signature Validated]

Allergy List

Allergen Name	Date	Reaction	Notes
PENICILLINS	--	swelling	--

Family Medical History

Disease Name	Relative/Age	Notes
Family History: Arthritis	/ Mother/	--

Social History

Finding	Status	Start/Stop	Quantity	Notes
Alcohol	Current every day	--/--	1-2/day	--
Drug Use	Never	--/--	--	--
Law Enforcement	--	--/--	--	--
Married	--	--/--	--	--
Patient Declines Flu Vaccinations	--	--/--	--	--
Tobacco	Former	15/74	1 ppd	--

Review of Systems

Constitutional
- **Denies** : fever, chills

Eyes
- **Denies** : changes in vision, blurred vision, impaired vision, double vision

HENT
- **Denies** : chronic sinus problems

Cardiovascular
- **Admits** : chest pain
- **Denies** : cardiac murmurs, irregular heart beats

Respiratory
- **Admits** : shortness of breath
- **Denies** : wheezing, cough

Gastrointestinal
- **Admits** : nausea, vomiting, constipation
- **Denies** : diarrhea, jaundice, blood in stools

Genitourinary
- **Denies** : urgency, frequency, dysuria, nocturia, hematuria, change in urine color, difficulty voiding

Integument
- **Denies** : rash, itching, new skin lesions

Neurologic
- **Denies** : tingling or numbness, muscular weakness, incoordination, seizures

Musculoskeletal
- **Admits** : back pain

Endocrine
- **Denies** : cold intolerance, heat intolerance, weight gain, weight loss

Psychiatric
- **Admits** : depression
- **Denies** : anxiety

Vitals

Date	Time	BP	Position	Site	L\R	Cuff Size	HR	RR	TEMP(°F)	WT	HT	BMI kg/m²	BSA m²	O2 Sat	HC
08/02/2012	01:15 PM	98/60	Sitting				76 R			202lbs 0oz	5' 11"	28.17	2.14		

Received
OCT 15 2012
CCMSI-Reno

Physical Examination

Constitutional
- **Appearance** : Well nourished, Normal body habitus

316

177

[Digital Signature Validated]

Eyes
- **Sclera** : Sclera white,

Neck
- **Inspection and Palpation** : normal appearance, no adenopathy
- **Thyroid** : Non-Tender. No Nodules

Chest
- **Inspection of Chest** : No Chest Deformity
- **Respiratory Effort** : Breathing unlabored

Cardiovascular
- **Heart** : Regular Rhythm and Rate
- **Peripheral Vascular System** :
  - **Carotid Arteries** : NO BRUITS
  - **Palmar Arteries** : Radial pulses Present
  - **Peripheral Circulation** : Capillary refill adequate

Gastrointestinal
- **Abdominal Exam** : Abdomen Non-tender, *moderate abdominal obesity*, no masses present

Lymphatic
- **Neck** : No Cervical Adenopathy

Skin
- **General Inspection** : Skin warm and dry

Neurologic and Psychiatric
- **Mental Status** :
  - **Mood and Affect** : Normal mood , normal affect
- **Gait and Station** : Able to stand without difficulty
- **Coordination** : Motor grossly symetrical

Assessment

- Biliary Dyskinesia 575.8
  reduced ejection fraction
  progressive biliary colic
- Alcohol dependence, continuous 303.91
  Still uses alcohol but reduced intake to several drinks per day
- Hiatal hernia 553.3
- Hypertension 401.9
- Liver cysts 573.8
- Benign Prostatic Hypertrophy 600.00
- Depressive Disorder 311

Plan

Orders
- CMP (80053) - - 08/02/2012
- CBC (automated, with hemogram and platelets) (85027) - - 08/02/2012
- INR (99363) - - 08/02/2012
- Prothrombin time; (85610) - - 08/02/2012
- PTT (85730) - - 08/02/2012
- Laparoscopic Cholecystectomy (47562) - - 08/05/2012

Instructions
- DISCUSSION:
- The patient has symptomatic gallbladder disease that I have recommended cholecystectomy. I have discussed the diagnosis, indications for removal of the gallbladder along with the risks and benefits of the surgery. Short term and long-term complications were discussed including post-cholecystectomy syndrome. Ample time was given to answer all questions. Verbal and written permission was obtained.
- PLAN:
- Handouts were reviewed with the patient.

Electronically Signed by: Myron J. Gomez, MD -Author on August 7, 2012 10:34:39 PM

Received
OCT 15 2012
CCMSI-Reno

317

178

[Digital Signature Validated]

347

AFFIRMATION
Pursuant to NRS 239B.030

The undersigned does hereby affirm that the preceding **INSURER'S DOCUMENTARY EVIDENCE**, filed in Nevada Department of Administration Appeal No. 44957-LLW does not contain the social security number of any person.

TIMOTHY E. ROWE, ESQ.
Attorneys for
CITY OF RENO

8-22-13
Date

McDONALD·CARANO·WILSON
100 WEST LIBERTY STREET, 10TH FLOOR • RENO, NEVADA 89501
P.O. BOX 2670 • RENO, NEVADA 89505-2670
PHONE 775-788-2000 • FAX 775-788-2020

CERTIFICATE OF SERVICE

Pursuant to NRCP 5(b), I hereby certify that I am an employee of McDONALD CARANO WILSON LLP, and that on the 23rd day of August, 2013, I served the within **INSURER'S DOCUMENTARY EVIDENCE** via Reno Carson Messenger Service in sealed envelopes addressed to the following:

Nevada Department of Administration
Appeals Office
1050 E. William St., Suite 450
Carson City, NV 89701

Evan Beavers, Esq. Deputy
Nevada Attorney for Injured Workers
1000 E. William St., #208
Carson City, NV 89701

Sandra Pelham

McDONALD·CARANO·WILSON
100 WEST LIBERTY STREET, 10th FLOOR • RENO, NEVADA 89501
PO BOX 2670 • RENO, NEVADA 89505-2670
PHONE 775-788-2000 • FAX 775-788-2020

373849

NEVADA DEPARTMENT OF ADMINISTRATION
BEFORE THE APPEALS OFFICER

In the Matter of the Contested
Industrial Insurance Claim of:

Claim No.: 12853C301824
1990204572
Hearing No.: 46538-SA
45822-KD
44686-SA
Appeal No.: 46812-LLW
46479-LLW
44957-LLW

DANIEL DEMARANVILLE
(DECEASED)

Claimant.
_____/

STATE OF NEVADA
DEPT OF ADMINISTRATION
HEARINGS DIVISION
APPEALS OFFICE
2014 FEB -3 PM 1:05
RECEIVED
AND
FILED

INSURER'S FIRST SUPPLEMENTAL DOCUMENTARY EVIDENCE

Index	Document Description	Page
9/19/13	EICN Correspondence (Appealed)	1
12/18/13	Order Transferring Hearing to Appeals Office	4

Records Received from EICN (not previously filed)

10/15/09-???	EKG	5
3/18/11	Reno Heart Physicians (w EKG reports)	11
8/5/12	Operative Notes	23
9/3/13	Sankar Pemmaraju, D.O. (Informal Review)	28
9/16/13	Yasmine S. Ali, M.D. (Informal Review)	33

ENTERED INTO
EVIDENCE AS EXHIBIT # 2

McDONALD·CARANO·WILSON
100 WEST LIBERTY STREET, 10TH FLOOR • RENO, NEVADA 89501
P.O. BOX 2670 • RENO, NEVADA 89505-2670
PHONE 775-788-2000 • FAX 775-788-2020

EMPLOYERS

PO Box 539004, Henderson, NV 89053-9004

September 19, 2013

Laura DeMaranville
PO BOX 261
Verdi, NV 89439-0261

RECEIVED
SEP 23 2013
McDonald Carano Wilson LLP

RE: Employee: DANIEL E DEMARANVILLE
Employer: RENO CITY OF
Date of Injury: 01/31/1990
Claim No. 1990204572
Insurer: Employers Insurance Company of Nevada

Dear Ms. DeMaranville:

It is the determination of the Employers Insurance Company of Nevada to deny liability of the above claim, as the doctor who completed the C4 form indicated that he could not directly connect this injury or occupational disease as job incurred.

> NRS 616C.150 Compensation prohibited unless preponderance of evidence establishes that injury arose out of and in course of employment; rebuttable presumption if notice of injury is filed after termination of employment.
> 1. An injured employee or the dependents of the injured employee are not entitled to receive compensation pursuant to the provisions of chapters 616A to 616D, inclusive, of NRS unless the employee or the dependents establish by a preponderance of the evidence that the employee's injury arose out of and in the course of his or her employment.
> 2. For the purposes of chapters 616A to 616D, inclusive, of NRS, if the employee files a notice of an injury pursuant to NRS 616C.015 after his or her employment has been terminated for any reason, there is a rebuttable presumption that the injury did not arise out of and in the course of his or her employment.
>
> NRS 617.358 Compensation prohibited unless preponderance of evidence establishes that disease arose out of and in course of employment; rebuttable presumption if notice of disease is filed after termination of employment; exceptions.
> 1. An employee or the dependents of the employee are not entitled to receive compensation pursuant to the provisions of this chapter unless the employee or the dependents of the employee establish by a preponderance of the evidence that the employee's occupational disease arose out of and in the course of his or her employment.
> 2. If the employee files a notice of an occupational disease pursuant to NRS 617.342 after his or her employment has been terminated for any reason, there is a rebuttable presumption that the occupational disease did not arise out of and in the course of his or her employment.
> 3. The provisions of this section do not apply to any claim filed for an occupational disease described in NRS 617.453, 617.455, 617.457, 617.485 or 617.487.

Additionally, there is no objective medical reporting to support the diagnoses listed on the C4 form of atherosclerotic heart disease and myocardial infarction. The medical reporting submitted was referred to our managed care organization and a review was completed by Yasmine S. Ali, M.D., M.S.C.I., F.A.C.C., F.A.C.P., who is board certified in Internal Medicine and Cardiovascular Disease. Dr. Ali's review report indicates there was no documentation in

(1)

the records that would support a diagnosis of atherosclerotic heart disease, and there is no evidence of myocardial infarction, particularly since cardiac enzymes were not drawn, a 12-lead ECG showing evidence of myocardial infarction is absent, and an autopsy was not performed. Thus, it appears most likely that the cardiac arrest was a post-operative complication. Dr. Ali's report also noted there was no evidence in the records of coronary artery disease, coronary heart disease or ischemic heart disease.

We have also been unable to obtain the physicals performed during the course of your employment as a police officer for the City of Reno. This is pursuant to Nevada Revised Statute (NRS) 617C.457, which states:

> NRS 617.457 Heart diseases as occupational diseases of firefighters, arson investigators and police officers.
>
> 1. Notwithstanding any other provision of this chapter, diseases of the heart of a person who, for 5 years or more, has been employed in a full-time continuous, uninterrupted and salaried occupation as a firefighter, arson investigator or police officer in this State before the date of disablement are conclusively presumed to have arisen out of and in the course of the employment.
>
> 2. Notwithstanding any other provision of this chapter, diseases of the heart, resulting in either temporary or permanent disability or death, are occupational diseases and compensable as such under the provisions of this chapter if caused by extreme overexertion in times of stress or danger and a causal relationship can be shown by competent evidence that the disability or death arose out of and was caused by the performance of duties as a volunteer firefighter by a person entitled to the benefits of chapters 616A to 616D, inclusive, of NRS pursuant to the provisions of NRS 616A.145 and who, for 5 years or more, has served continuously as a volunteer firefighter in this State by continuously maintaining an active status on the roster of a volunteer fire department.
>
> 3. Except as otherwise provided in subsection 4, each employee who is to be covered for diseases of the heart pursuant to the provisions of this section shall submit to a physical examination, including an examination of the heart, upon employment, upon commencement of coverage and thereafter on an annual basis during his or her employment.
>
> 10. Failure to correct predisposing conditions which lead to heart disease when so ordered in writing by the examining physician subsequent to a physical examination required pursuant to subsection 3 or 4 excludes the employee from the benefits of this section if the correction is within the ability of the employee.

If you or your employer disagrees with this decision, you have the right to file an appeal and mail it directly to the Hearing Officer, Department of Administration, 1050 E. Williams St., Ste 400, Carson City, Nevada 89701. If your request does not reach the Hearings Division within seventy (70) days from the date of this letter, you may lose your right to appeal the decision.

If you have any questions, please contact our customer service center at 1-888-682-6671.

Sincerely,

Amy Caldera
Sr Claims Adjuster

Enclosure: C4

(2)

Request for Hearing

cc: RENO CITY OF
DIR

(3)

323

353

STATE OF NEVADA
DEPARTMENT OF ADMINISTRATION
HEARINGS DIVISION

In the matter of the Contested Industrial Insurance Claim of:

DANIEL DEMARANVILLE, DECEASED
C/O LAURA DEMARANVILLE
PO BOX 261
VERDI, NV 89439

Hearing Number: 46538-SA
Claim Number: 12853C301824

CITY OF RENO
ATTN CARA BOWLING
PO BOX 1900
RENO, NV 89505

/

ORDER TRANSFERRING HEARING TO APPEALS OFFICE

The Employer's Request for Hearing was filed on November 17, 2013.

The requesting party appealed the Insurer's determination dated September 19, 2013.

The parties have filed a stipulation to waive a hearing at the Hearing Officer level and to proceed directly to the Appeals Officer level.

> **NRS 616C.315(7)** provides that the parties to a contested claim may, if the Claimant is represented by counsel, agree to forego a hearing before a Hearing Officer and submit the contested claim directly to an Appeals Officer.

THEREFORE, good cause appearing, the Hearing Officer proceeding is **DISMISSED** and this matter shall be and hereby transferred to the Appeals Officer for further proceedings.

NOTICE: If any party objects to this transfer to the Appeals Office, an objection thereto must be filed with the Appeals Office at 1050 E. Williams Street #450, Carson City, Nevada 89701, within 15 days of this order.

IT IS SO ORDERED this 18th day of December, 2013.

Sondra L Amodei, Hearing Officer

Consol
46812-LLW
Tues 2-11-14 1:30

RECEIVED AND FILED
2013 DEC 18 AM 10:25
STATE OF NEVADA
DEPT OF ADMINISTRATION
HEARINGS DIVISION
APPEALS OFFICE

(4)

354 324

355

325

EMPLOYERS07/30/2013 11:33:51 H3

ID:

10/15/09 9:52:08

DEMARANVILLE,DANIEL
ID:

10/15/09 9:52:08

D.O.B.: 10/04/1934 75 YEARS
MALE
Meds:
Class:
Loc: 12

Vent. Rate:	75 bpm
P Duration:	102 ms
QRS Duration:	152 ms
PR Interval:	166 ms
QT Interval:	408 ms
QTc Interval:	434 ms
P-R-T AXIS:	75° 104° 63°

SINUS RHYTHM
Low terminal QRS spatial velocity
Broad R or R' in V1 or V2
RIGHT BUNDLE BRANCH BLOCK

Summary: ABNORMAL

* Unconfirmed Analysis

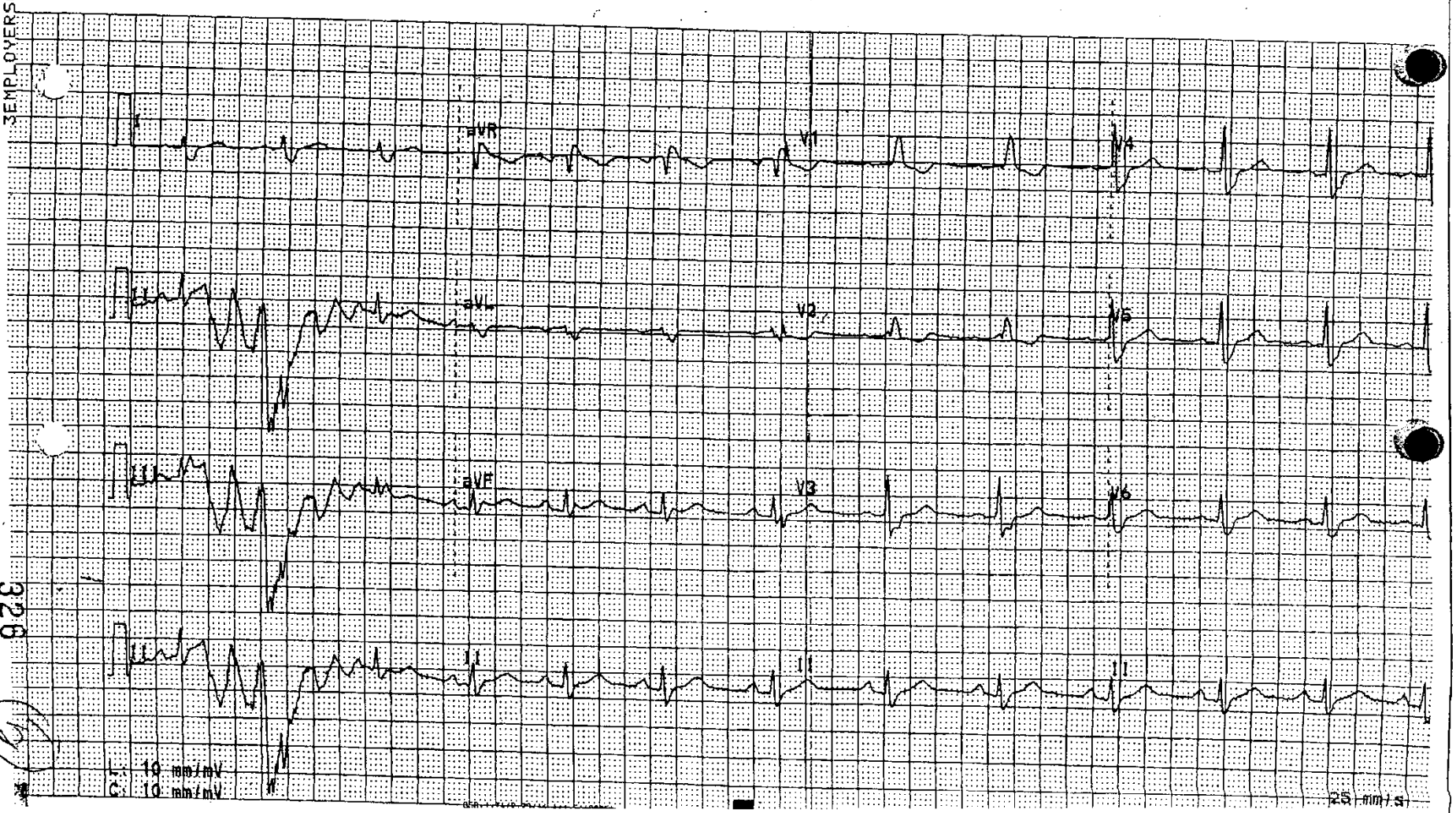

EMPLOYERS07/30/2013 11:33:51 H3

ID: 304 28-1477

ID:

D.O.B.: 10/04/1934 75 YEARS
MALE
Meds:
Class:
Loc: 12

Vent. Rate:	75 bpm
P Duration:	102 ms
QRS Duration:	152 ms
PR Interval:	166 ms
QT Interval:	408 ms
QTc Interval:	434 ms
P-R-T AXIS:	75° 104° 63°

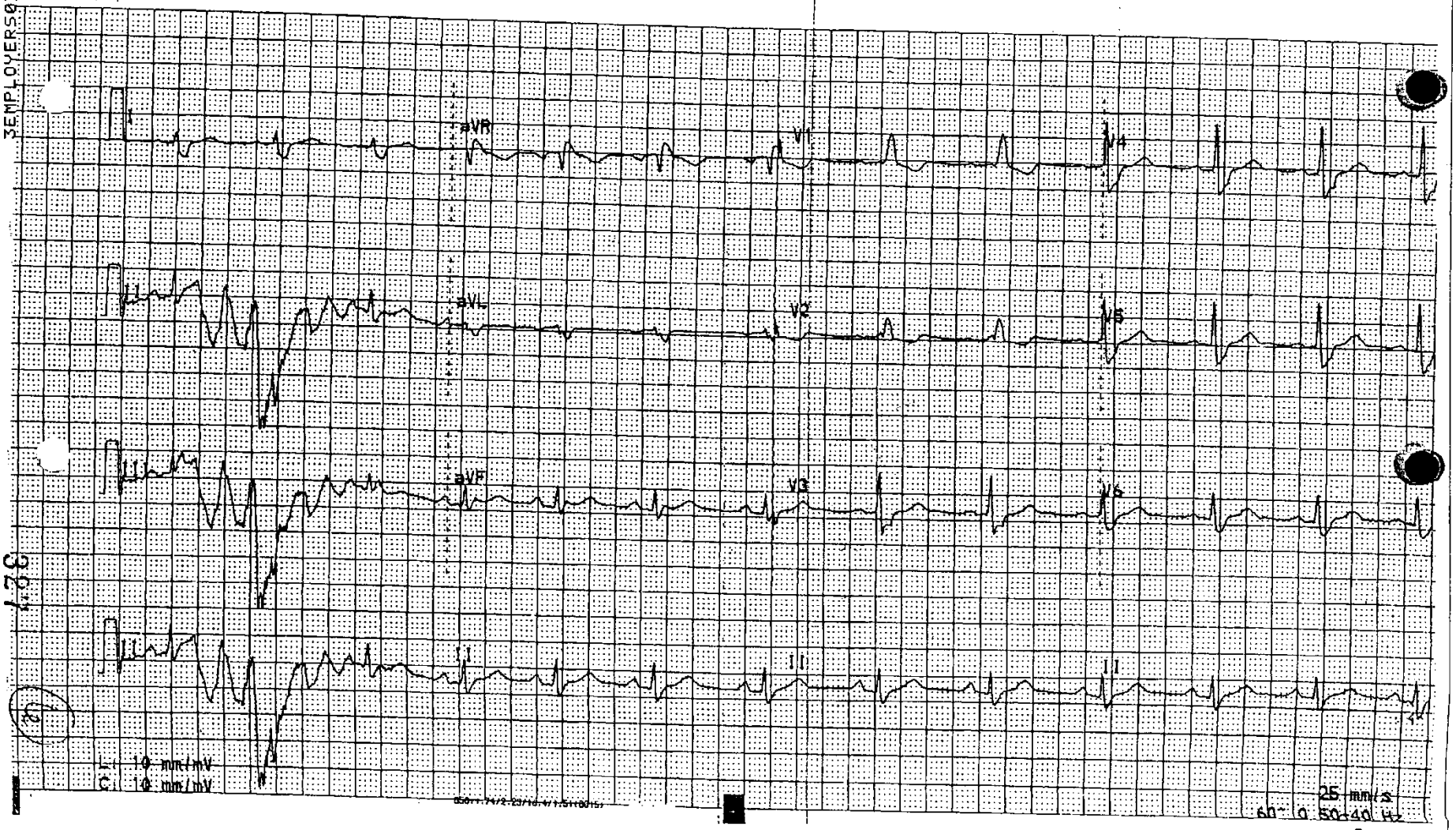

357

376

SA 369

3EMPLOYER507/30/2013 11:33:52 H3

ID:

D.O.B.: 10/04/1934 75 YEARS
MALE
Meds:
Class:
Loc: 12

Vent. Rate:	75 bpm
P Duration:	100 ms
QRS Duration:	144 ms
PR Interval:	170 ms
QT Interval:	410 ms
QTc Interval:	434 ms
P-R-T AXIS:	77° 102° 66°

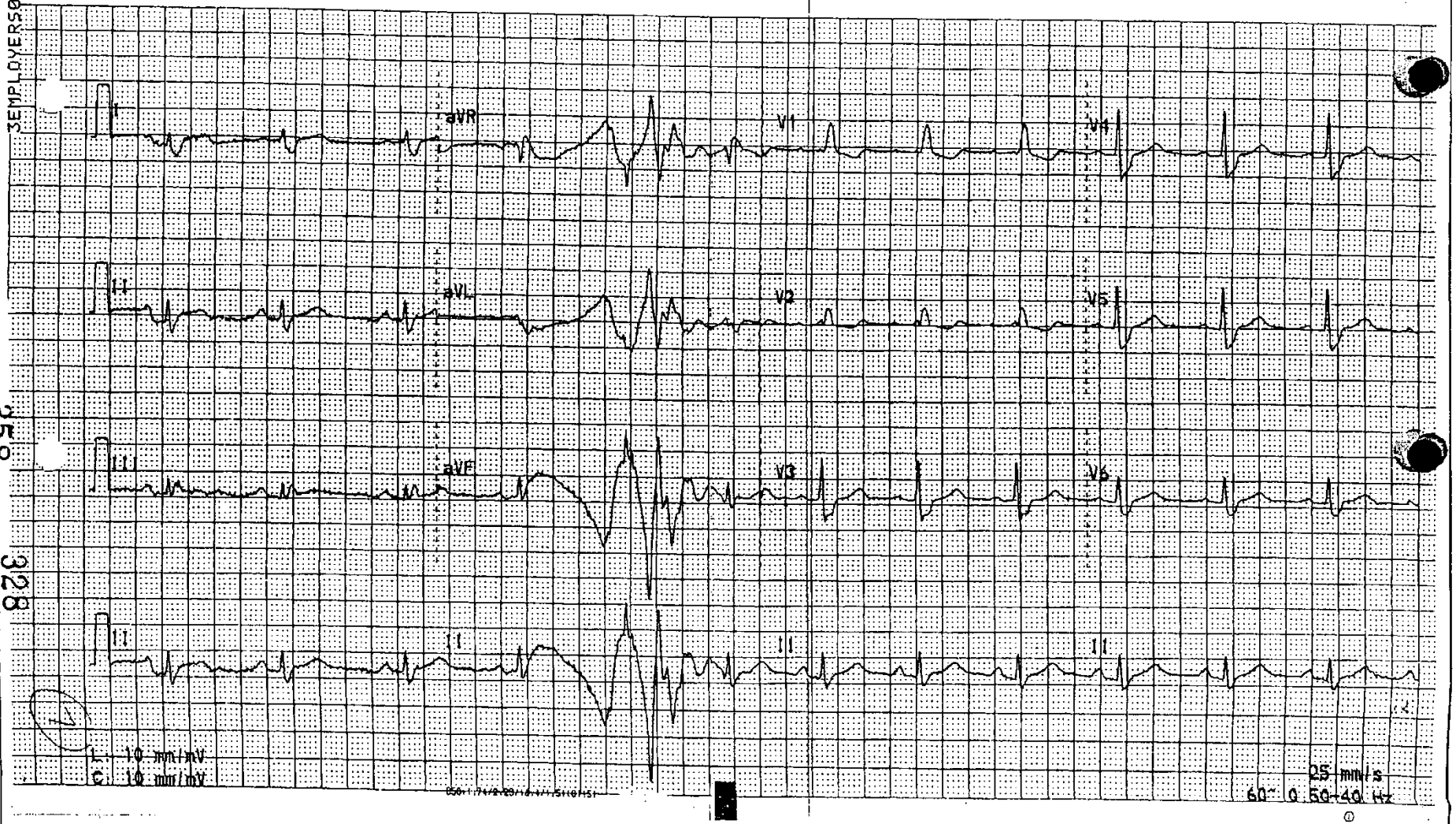

358

328

SA 370

3EMPLOYERS07/30/2013 11:33:52 H3

D.O.B.: 10/04/1934 75 YEARS
MALE
Meds:
Class:
Loc: 12

Vent. Rate: 75 bpm
P Duration: 100 ms
QRS Duration: 144 ms
PR Interval: 170 ms
QT Interval: 410 ms
QTc Interval: 434 ms
P-R-T AXIS: 77° 102° 66°

SINUS RHYTHM
Low terminal QRS spatial velocity
Broad R or R' in V1 or V2
RIGHT BUNDLE BRANCH BLOCK

Summary: ABNORMAL
* Unconfirmed Analysis *

- RBBB
- unable to interp ST due to RBBB -
- sinus rhythm
- poss old Infarct

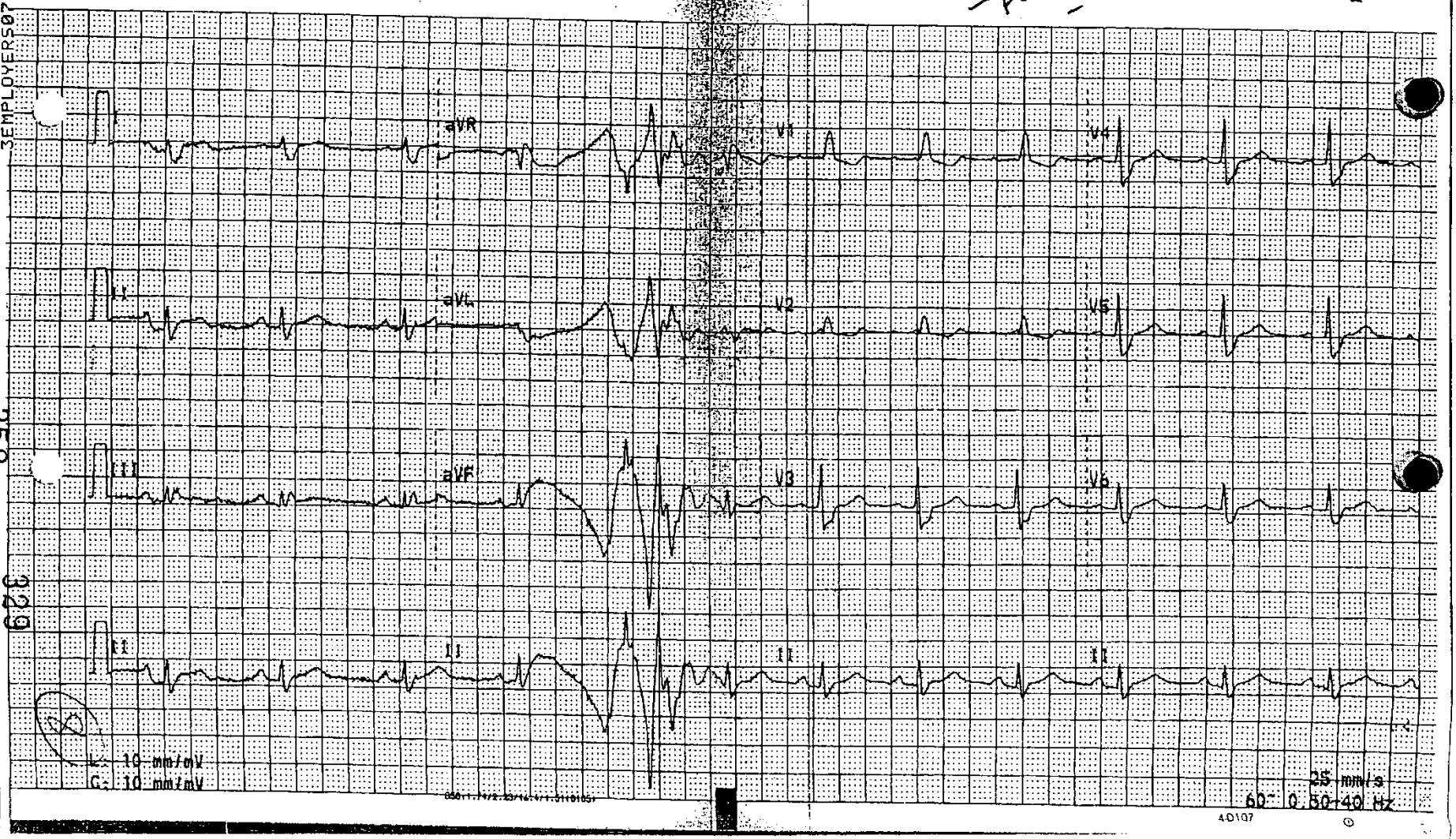

359

329

SA 371

3EMPLOYERS07/30/2013 11:33:53 H3

ID: #STAT#1081015161056

D.O.B.:
Meds:
Class:
Loc: 1

Daniel Desmarouville

Vent. Rate:	75 bpm
P Duration:	104 ms
QRS Duration:	154 ms
PR Interval:	168 ms
QT Interval:	422 ms
QTc Interval:	446 ms
P-R-T AXIS:	77° 0° 62°

ID: #STAT#1081015161056

SINUS RHYTHM
INTERPRETATION MADE WITHOUT KNOWLEDGE OF PATIENT'S SEX AND AGE.
INDETERMINATE FRONTAL QRS AXIS
Low terminal QRS spatial velocity
Broad R or R' in V1 or V2
RIGHT BUNDLE BRANCH BLOCK

Summary: ABNORMAL

* Unconfirmed Analysis *

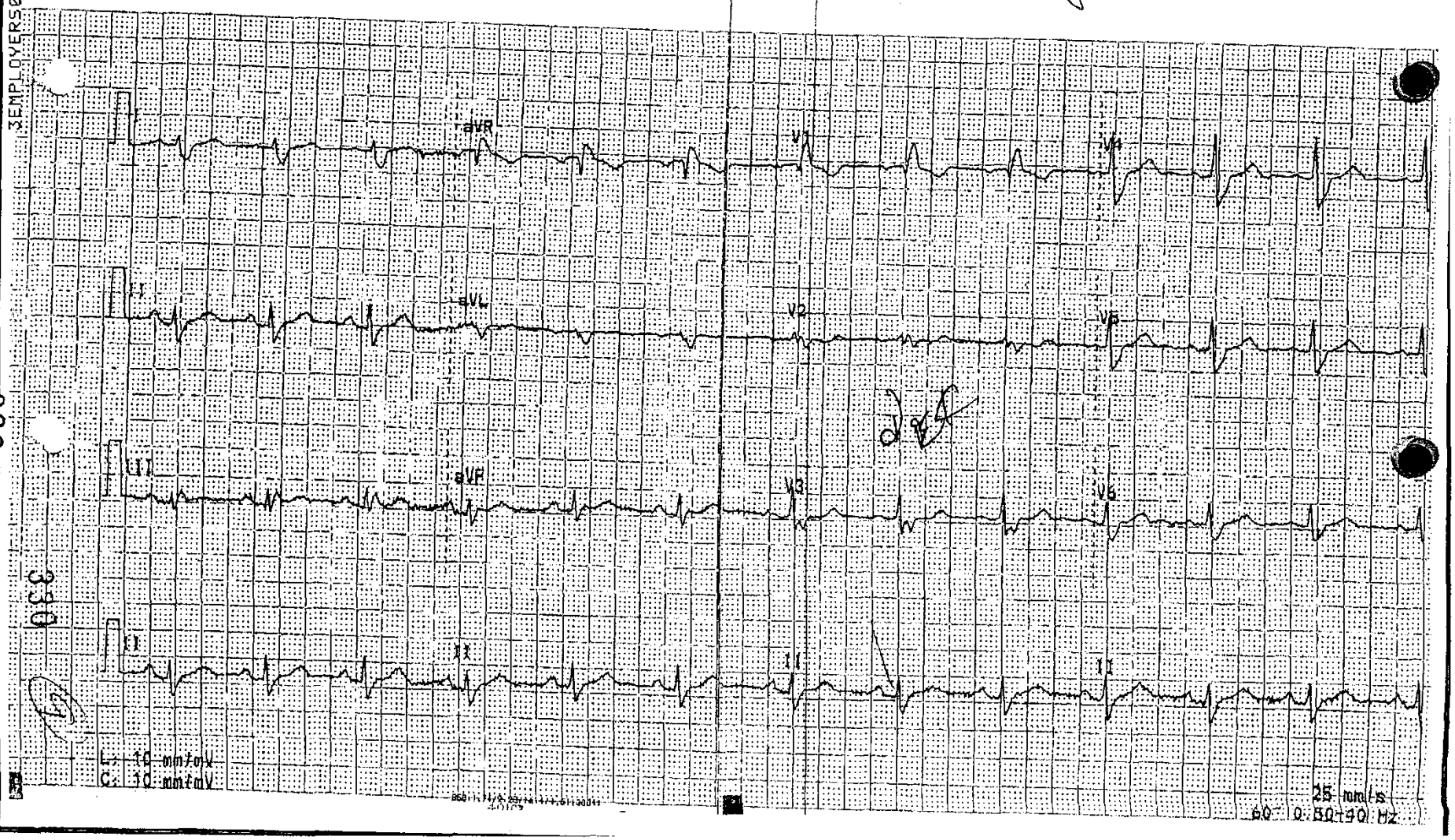

360

330

3EMPLOYERS07/30/2013 11:33:53 H3

ID: #STAT#1081015161056

D.O.B.:
Meds:
Class:
Loc: 1

Vent. Rate:	75 bpm
P Duration:	104 ms
QRS Duration:	154 ms
PR Interval:	168 ms
QT Interval:	422 ms
QTc Interval:	446 ms
P-R-T AXIS:	77° 0° 62°

ID: #STAT#1081015161056

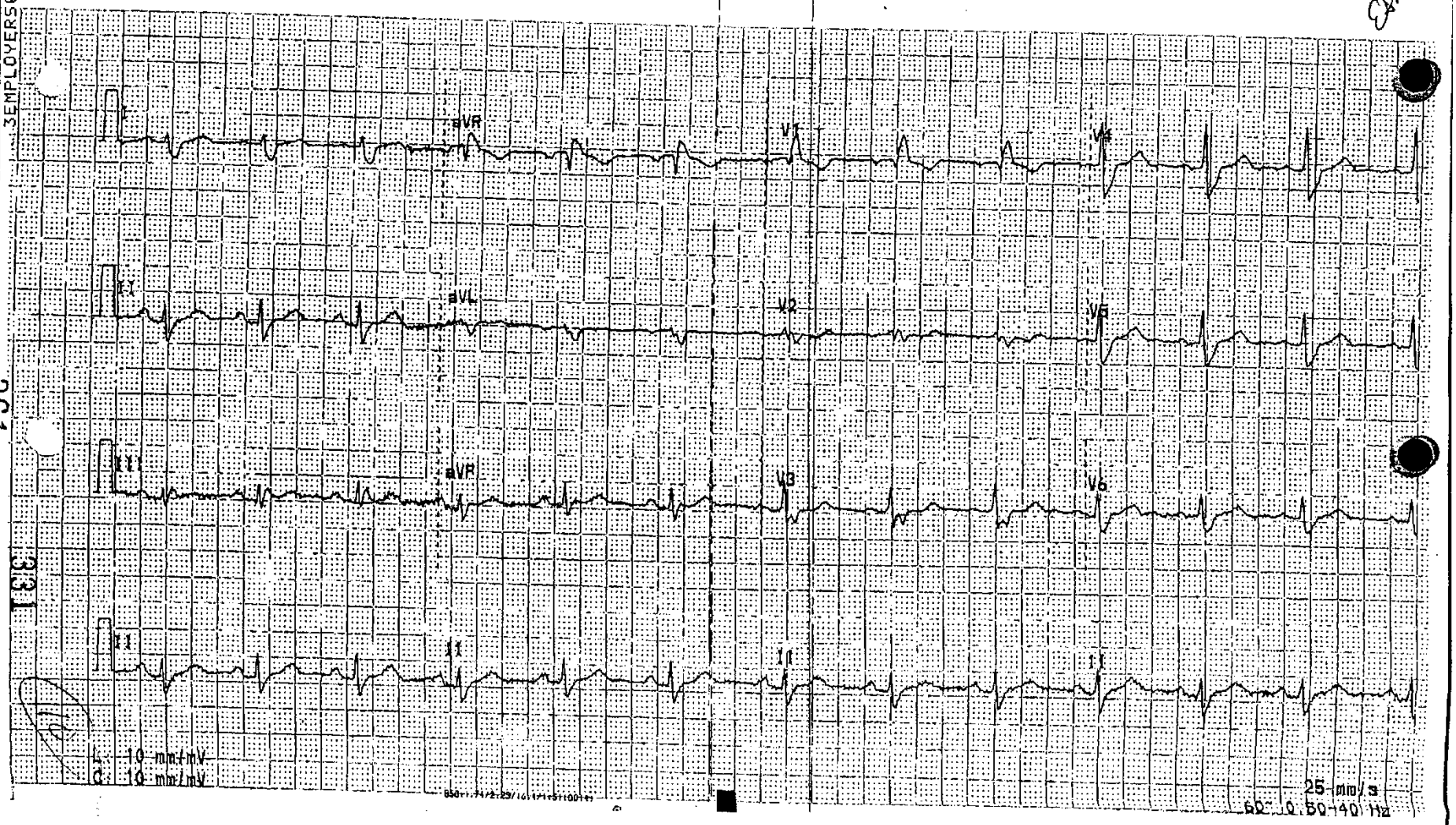

361

331

SA 373

RENO HEART PHYSICIANS
CARSON HEART PHYSICIANS

1500 E 2nd St. Reno, NV 89502 | P. (775) 323-6700 | F. (775) 325-3489
343 Elm St., Ste. 400, Reno, NV 89520 | P. (775) 323-6700 | F. (775) 327-8191
2874 N. Carson St., Ste. 120, Carson City, NV 89706 | P. (775) 841-6700 | F. (775) 283-3260
www.RenoHeart.com

Cardiac Nuclear Medicine, Cardiac and Vascular Ultrasound Imaging

Stress Echocardiogram

Name: Damaranville, Daniel **Patient ID:** 795450 **Gender:** M
Exam Date: 03/28/2011 **HR:** 83 **Rhythm:** RBBB
DOB: 10/4/1934 **Age:** 76 Yrs **Left BP:** 140/84 mmHg
Height: 71 inches **Weight:** 214 lb **BSA:** 2.1 m^2
Reading Physician: Jerry Zebrack, MD **Sonographer:** B. Reagan
Referring Physician: Richard P. Ganchan, MD **CC:** Donald Van Dyken, MD
Indications: Abnormal EKG

TREADMILL, EKG, AND ECHO DATA SUMMARY — **Echo exam quality: Adequate**

Exercise Protocol	
Protocol: Bruce	
Total minutes: 4:30	
Reason for stopping: Shortness of breath Back Pain	
FAI: +20	**METS:** 7.0

EKG Data
Pre-exercise EKG: Right bundle branch block. Normal sinus rhythm.
Exercise EKG: Right bundle branch block.

Heart Rate and Blood Pressure
Resting blood pressure: 140/84
Baseline heart rate: 88
Percent of Age-Predicted MHR: 99%
Blood pressure at peak exercise: 160/80
Maximum heart rate achieved: 143

EKG SUMMARY

1. Sensitivity is decreased because of RBBB.
2. No angina or anginal equivalent.
3. Exercise capacity was moderately decreased.
4. Normal heart rate response to exercise.
5. Normal blood pressure response to exercise.
6. No arrhythmias were observed.

ECHOCARDIOGRAM FINDINGS

- **Rest Echo Study:** Ejection fraction at rest = 67%. Cardiac chamber sizes and LV systolic function are normal at rest. No resting wall motion abnormalities noted.
- **Immediate Post-Exercise Echo Study:** Appropriate augmentation of left ventricular function after maximal exercise with decrease in end-systolic dimensions. No immediate post exercise abnormalities noted but technically suboptimal study.

IMPRESSION

Borderline EF

REST Score: 1.0	IMPOST Score: 1.0	
		1 Normal; 2 Hypokinetic; 2 Hypokinetic (Mild); 2 Hypokinetic (Moderate); 2 Hypokinetic (Severe); 2 Hypokinetic (Borderline); 1 Hyperkinetic; 1 Akinetic/; 1 Dyskinetic; 1 Dilated and Thinned; x Not Visualized

Signature:

Jerry N. Zebrack, M.D.
Electronically Signed 3/28/2011 3:04 PM

Received
OCT 15 2012
CCMSI-Reno

DONALD VAN DYKEN M.D.

FAXED
MAR 29 2011
By

ICAEL
MAR 29 2011
332

(11)

362

SA 374

Daniel Demaranville

64 years
206 lb 71 in

29 MAR 99 16:32:36

74 living .16/.06/.26
wit.

PAL 134430

ACAdia Medical Group



(12)

333

363

DEMARANVILLE,DANIEL 10/13/05 10:45:41
ID:

D.O.B.: 10/04/1934 71 YEARS		Vent. Rate:	79 bpm
MALE		P Duration:	100 ms
Meds: NO MEDICATION		QRS Duration:	146 ms
Class:		PR Interval:	156 ms
Loc: 11		QT Interval:	408 ms
		QTc Interval:	439 ms
		P-R-T AXIS:	71° 108° 59°

Received
OCT 16 2012
CCMBT-Pasco

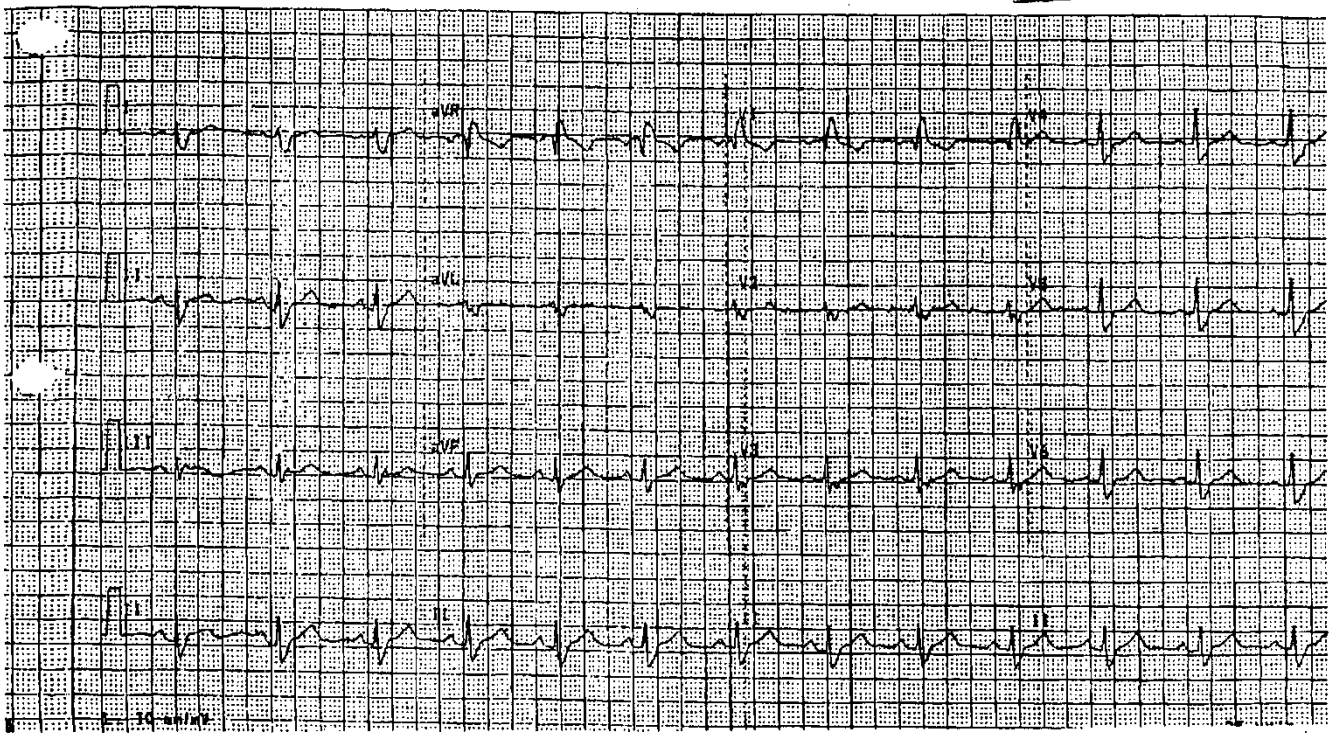

(13)

DEMARANVILLE,DANIEL 10/13/06 14:31:58
ID:

DEMARANVILLE,DANIEL 10/13/06 14:31:58
ID:

D.O.B.: 10/04/1934 72 YEARS
MALE
Meds: NO MEDICATION
Class:
Loc: 1

Vent. Rate:	79 bpm
P Duration:	106 ms
QRS Duration:	152 ms
PR Interval:	168 ms
QT Interval:	424 ms
QTc Interval:	455 ms
P-R-T AXIS:	70° 115° 58°

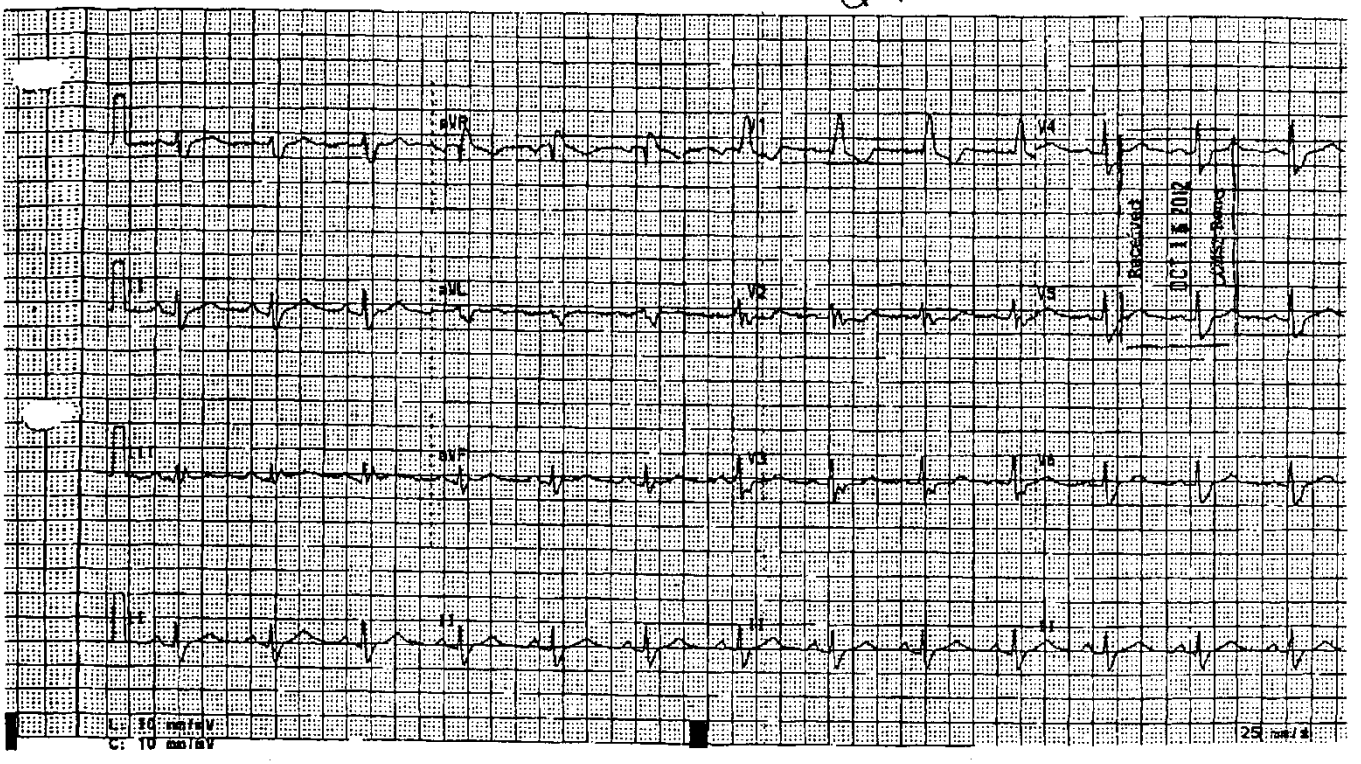

(14)

Name: Daniel Damaranville
ID: 504281477 10/15/2007 8:41:16 AM

HR: 78
BP: 128/69
Age: 73 Years
Gender: Male
Race: Caucasian
Height: 70 in
Weight: 206 lbs

Medication(s): zantac
Department:
Technician: Sofia
Physician: DR. PANACARI

	I	aVR	V1	V4
L	0.2	-0.7	-0.6	0.5
S	3.5	-4.5	-7.0	4.6

	II	aVL	V2	V5
L	1.1	-0.3	0.0	0.6
S	5.7	0.9	1.2	4.6

	III	aVF	V3	V6
L	0.9	1.0	0.2	0.6
S	1.3	3.8	2.3	3.9

Baseline ECG

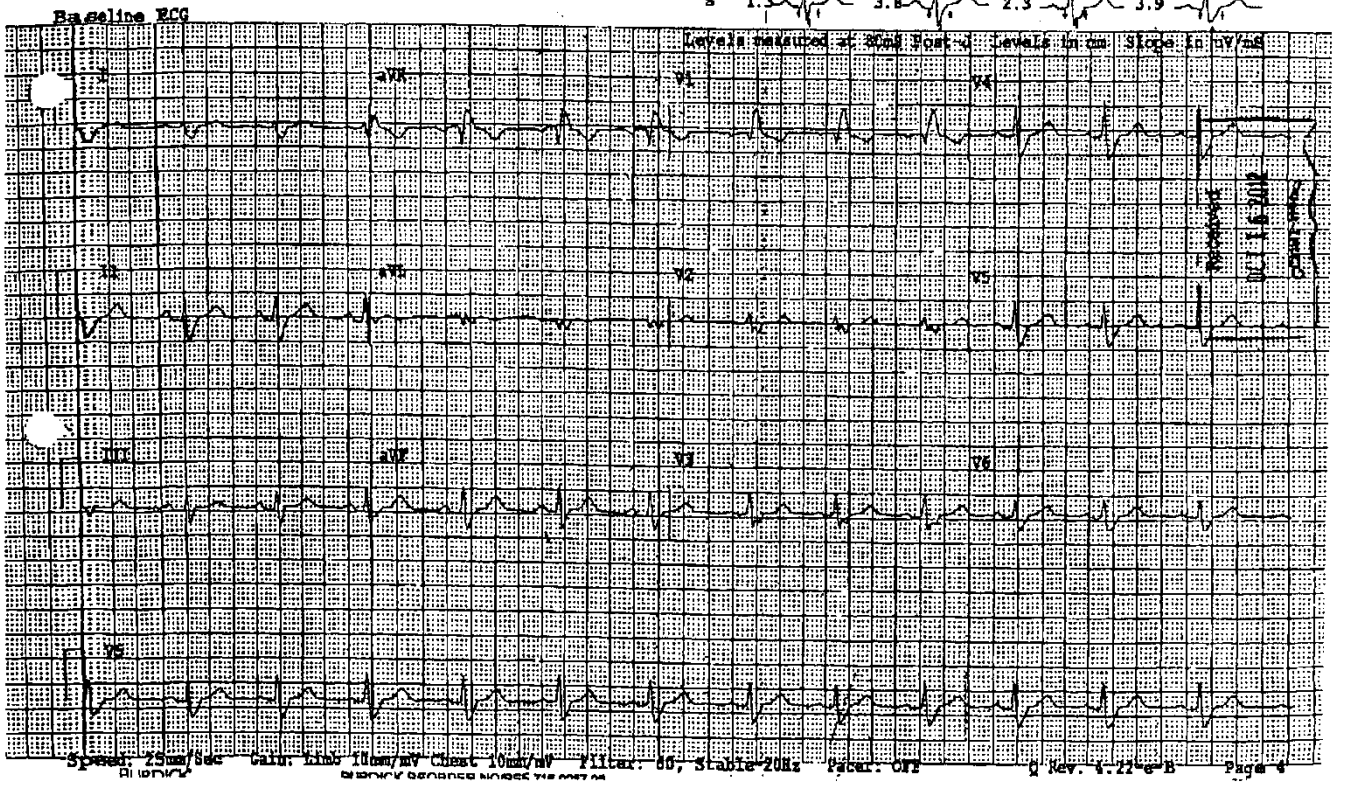

(15)

336

366

ID:	10/15/09 9:52:08	DENARANVILLE,DANIEL ID:	10/15/09 9:52:08

D.O.B.: 10/04/1934 75 YEARS
MALE
Meds:
Class:
Loc: 12

Vent. Rate:	75 bpm
P Duration:	102 ms
QRS Duration:	152 ms
PR Interval:	166 ms
QT Interval:	408 ms
QTc Interval:	434 ms
P-R-T AXIS:	75° 104° 63°

SINUS RHYTHM
Low terminal QRS spatial velocity
Broad R or R' in V1 or V2
RIGHT BUNDLE BRANCH BLOCK

Summary: ABNORMAL

* Unconfirmed Analysis

Received
OCT 1 5 2012

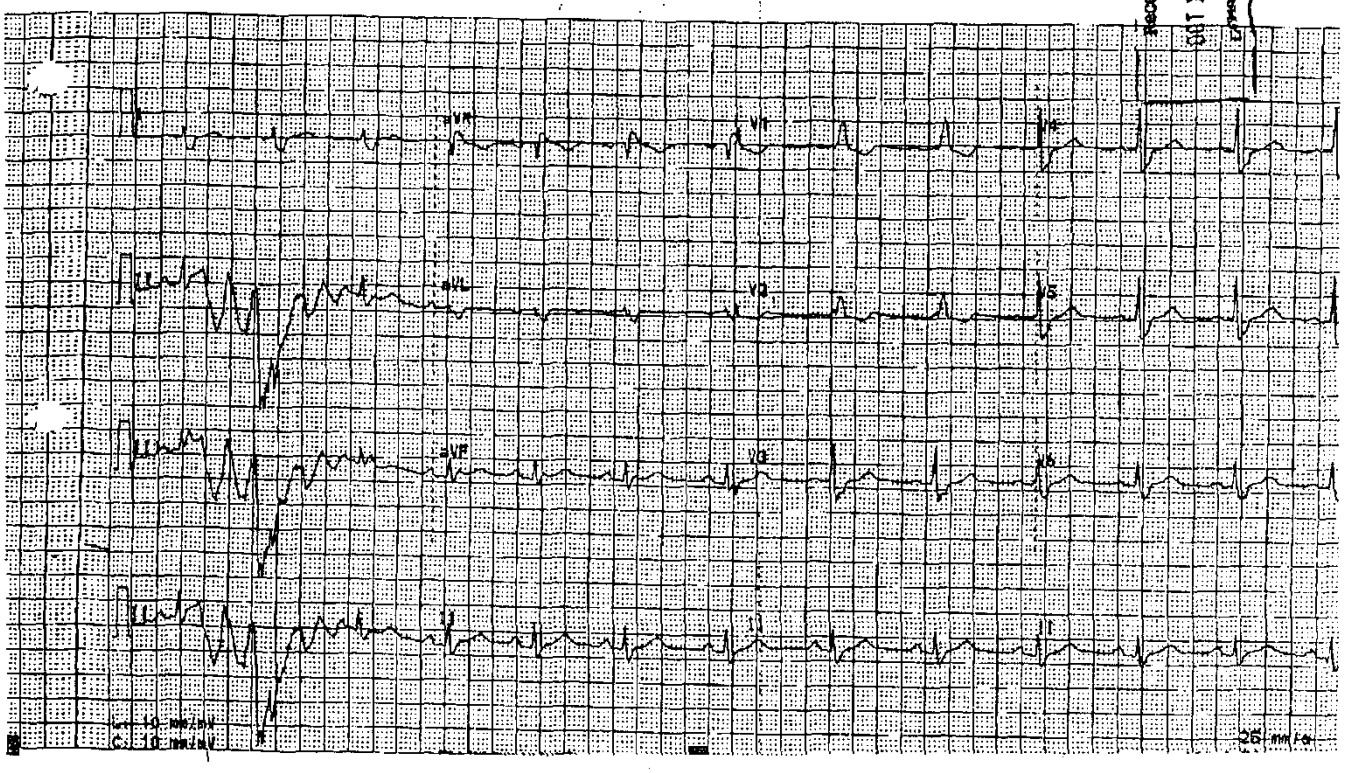

367 337

ID: ID:

D.O.B.: 10/04/1934 75 YEARS	Vent. Rate:	75 bpm
MALE	P Duration:	102 ms
Meds:	QRS Duration:	152 ms
Class:	PR Interval:	166 ms
Loc: 12	QT Interval:	408 ms
	QTc Interval:	434 ms
	P-R-T AXIS:	75° 104° 63°

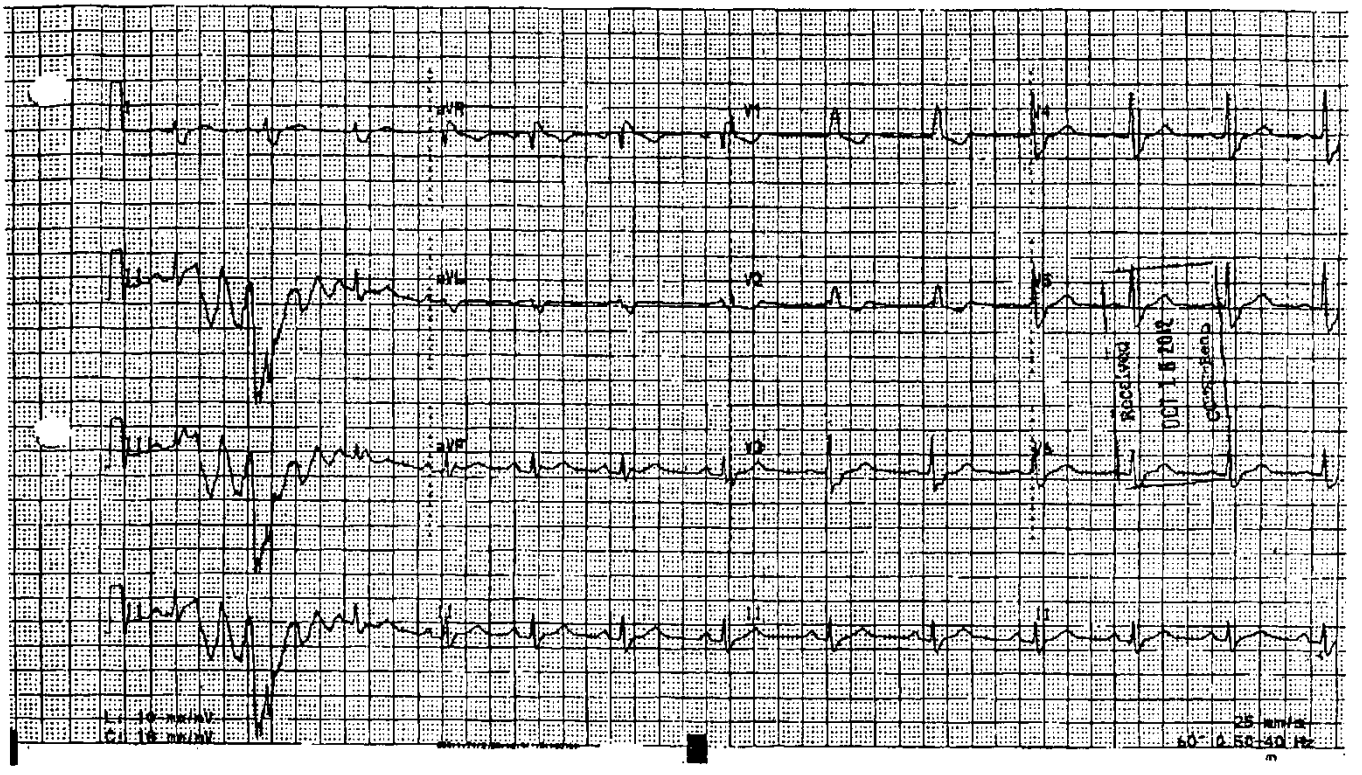

(17)

368 338

D.O.B.: 10/04/1934 75 YEARS
MALE
Meds:
Class:
Loc: 12

Vent. Rate:	75 bpm
P Duration:	100 ms
QRS Duration:	144 ms
PR Interval:	170 ms
QT Interval:	410 ms
QTc Interval:	434 ms
P-R-T AXIS:	77° 102° 66°

Received
OCT 16 2012

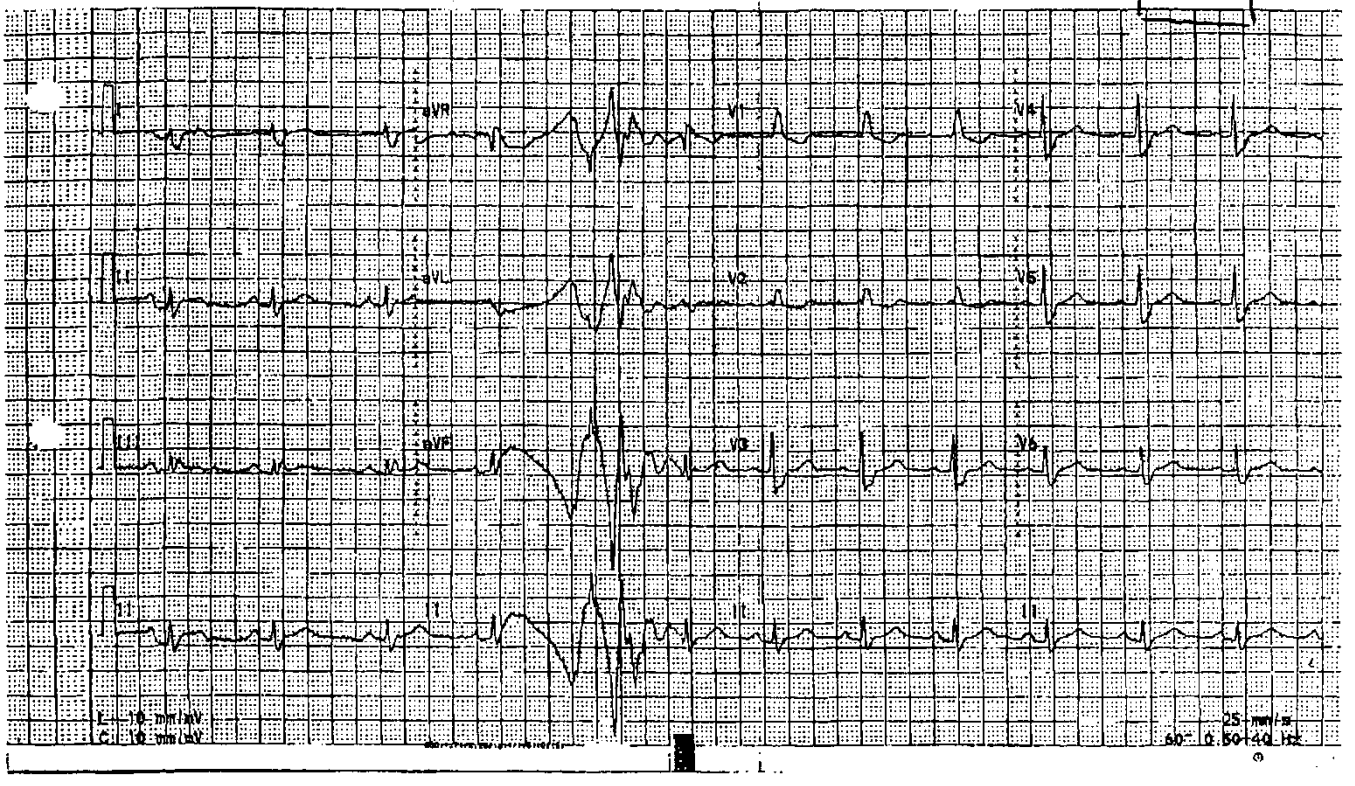

369 339

D.O.B.: 10/04/1934 75 YEARS
MALE
Meds:
Class:
Loc: 12

Vent. Rate:	75 bpm
P Duration:	100 ms
QRS Duration:	144 ms
PR Interval:	170 ms
QT Interval:	410 ms
QTc Interval:	434 ms
P-R-T AXIS:	77° 102° 66°

SINUS RHYTHM
Low terminal QRS spatial velocity
Broad R or R' in V1 or V2
RIGHT BUNDLE BRANCH BLOCK

Summary: ABNORMAL
* Unconfirmed Analysis *

- RBBB
- unable to interp ST due to RBBB -
- sinus rhythm
- poss old Infarct

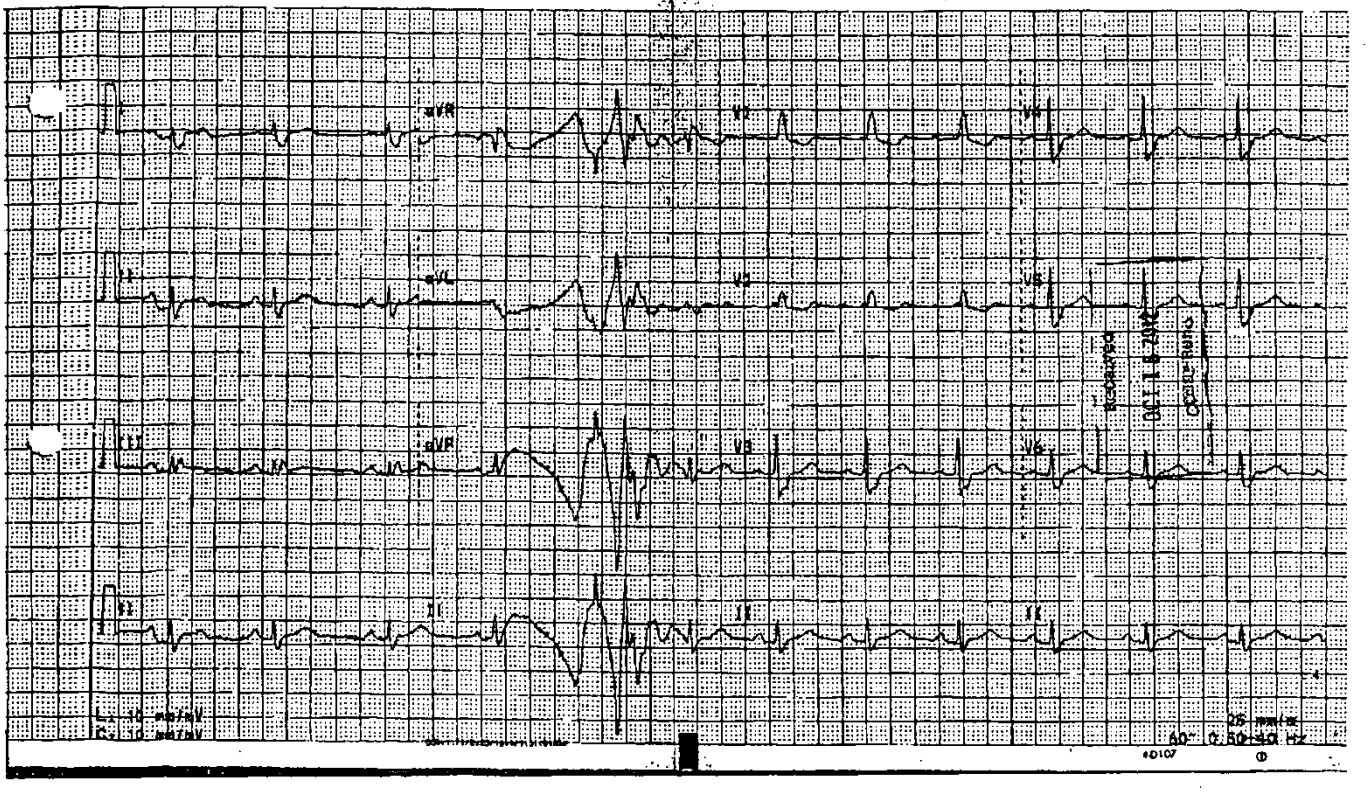

(19)

340

370

ID: #STAT#1081015161056

D.O.B.:
Made:
Class:
Loc: 1

Daniel Desmarteau

Vent. Rate:	75 bpm
P Duration:	104 ms
QRS Duration:	154 ms
PR Interval:	168 ms
QT Interval:	422 ms
QTc Interval:	446 ms
P-R-T AXIS:	77° 0° 62°

ID: #STAT#1081015161056

SINUS RHYTHM
INTERPRETATION MADE WITHOUT KNOWLEDGE OF PATIENT'S SEX AND AGE.
INDETERMINATE FRONTAL QRS AXIS
Low terminal QRS spatial velocity
Broad R or R' in V1 or V2
RIGHT BUNDLE BRANCH BLOCK

Summary: ABNORMAL

* Uncomfirmed Analysis *

Received OCT 15 2012 COMPLIANCE

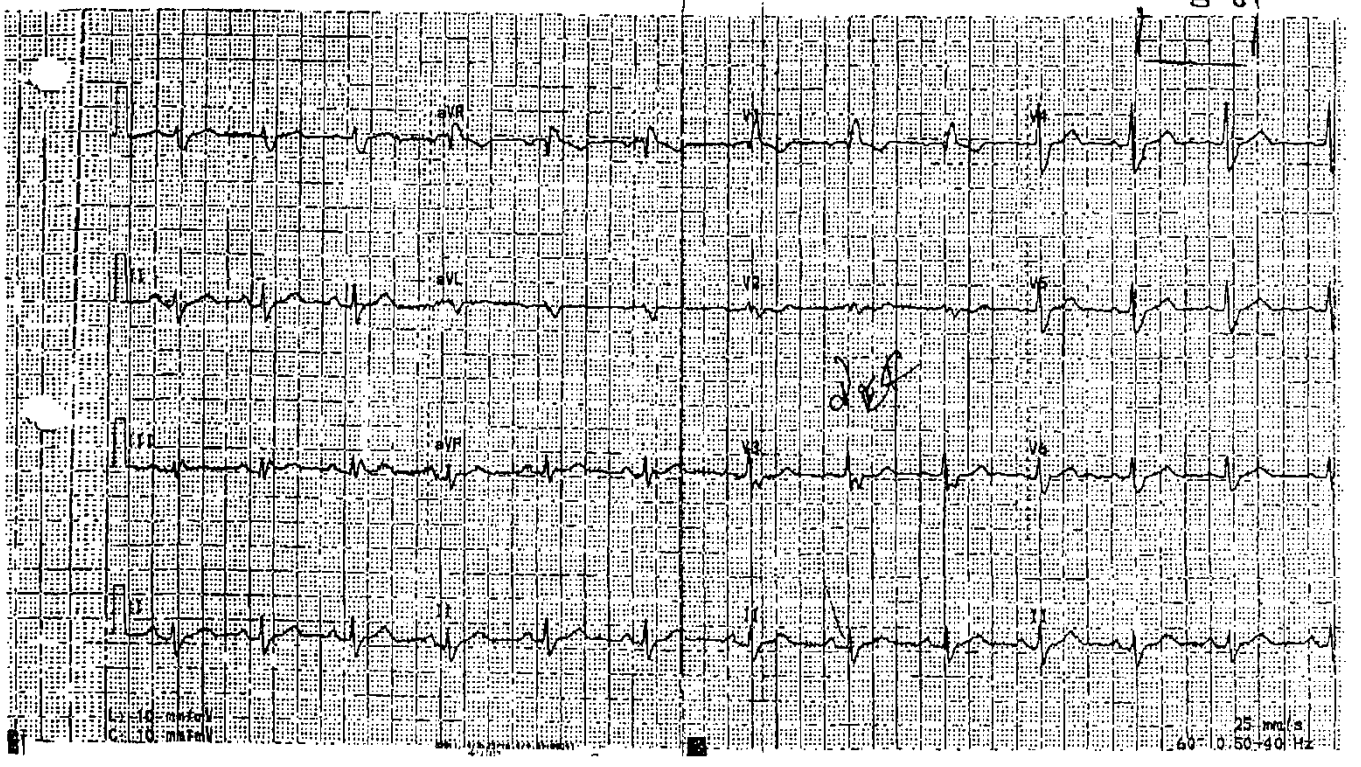

20

371 341

ID: #STAT#1081015161056

D.O.B.:
Meds:
Class:
Loc: 1

Vent. Rate:	75 bpm
P Duration:	104 ms
QRS Duration:	154 ms
PR Interval:	168 ms
QT Interval:	422 ms
QTc Interval:	446 ms
P-R-T AXIS:	77° 0° 62°

ID: #STAT#1081015161056

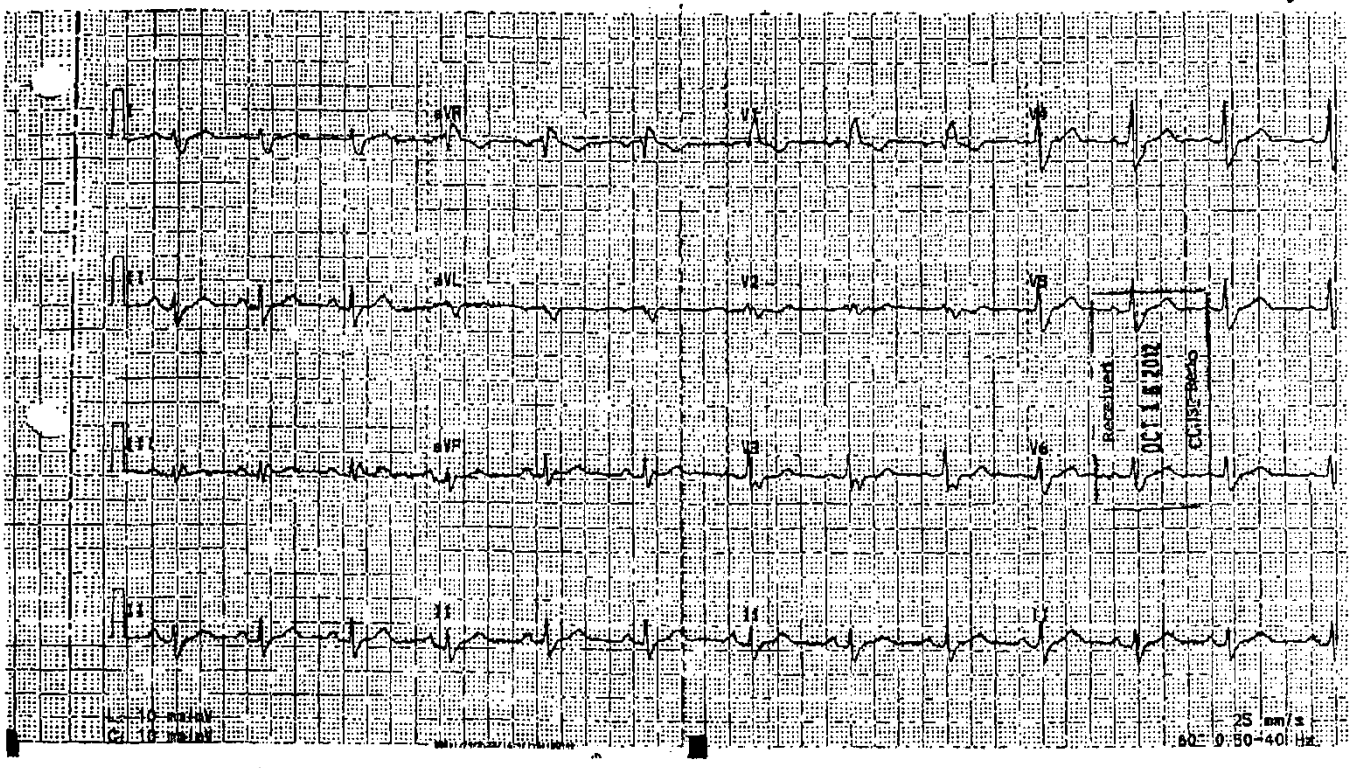

(21)

372 342

Date 08/05/12 Time Event Recognized 1908 Location TT PACU Witnessed: ☑ Yes ☐ No Code Blue Team Activated: ☐ Yes ☑ No Time _____

Illness Category: ☐ Medical Cardiac ☐ Trauma ☐ Medical Non-cardiac ☐ Obstetric ☐ Surgical Cardiac ☒ Surgical Non-cardiac

Condition when need for compressions/defibrillation was identified: ☒ Pulseless ☐ Pulse(poor perfusion)
Did patient with pulse requiring compressions become pulseless: ☐ Yes ☐ No
Conscious at onset: ☐ Yes ☒ No Monitoring at onset: ☒ ECG ☒ Pulse Oximeter ☐ Apnea

Airway/Ventilation

Breathing: ☐ Spontaneous ☒ Apneic ☐ Agonal ☐ Assisted
Time of First Assisted Ventilation: 1909
Ventilation: ☒ Bag-Valve-Mask ☐ Endotracheal Tube ☐ Tracheostomy ☐ Other _____
Intubation: Time 1910 Size 8.5 By whom Dr. Ellis
Confirmation: ☐ Auscultation ☒ Exhaled CO_2 ☐ Other _____

Circulation

1st Rhythm requiring compressions: PEA
Compressions: ☐ None ☒ Manual ☐ Device: _____
Time chest compressions started: 1908
Monitor/Defibrillator Type: ☐ Monophasic ☒ Biphasic ☐ AED
Time Applied: 1909

Conclusion

Time Resuscitation Ended: 1918
Reason:
☐ Survived-Return of Circulation (ROC) >20 min
☒ Died- Medical Futility
☐ Died- Advance Directives
☐ Died- Restrictions by Family

Time	Breathing: Spontaneous Rate	Breathing: Assisted Rate with BV	Pulse: Spontaneous Rate	Pulse: Compressions Rate	BP	RHYTHM	Defibrillator Joules	O_2 Saturation	Atropine Mg/Route IV	Epinephrine Mg/Route IV	Lidocaine Mg/Route IV	Vasopressin Units/Route IV	Amiodarone Mg/Route IV			Dopamine Mcg/Kg/Min	Dobutamine Mcg/Kg/Min	Epinephrine Mcg/Kg/Min	Norepinephrine Mcg/Min	Comments: Line placement, IO, Chest tube, Response to interventions, other Medications
1908	∅	✓	30	—	44/30	Brady/PEA		64												
1909		✓		100		PEA														
1911										1mg										
1912									1mg											
1913										1mg										
1914									1mg	1mg										
1915						PEA														1 Amp NaHCO3 IV
1916						asystole														ECHO done

Recorder R Altenger RN ID# 19543
RN Team Leader _____ ID# _____
Respiratory _____ ID# _____
Pharmacist _____ ID# _____
Physician Dr. Ellis Print
Dr. Cuneo
Dr. Baikary

Renown Logo

Patient Addressograph
M - DEMARANVILLE,DANIEL EUGE
HAR: 2446917 MR: 3305354
DOB: 10/4/1934 ADM: 8/5/2012
GOMEZ, MYRON J
8501392300

File Original Under Progress Notes — Yellow Copy to Nursing Office Mail Stop L-12

Code Blue Record

Modified from American Heart Associations' NRCPR

Revised 3/26/2010

PREOP ASSESSMENT

Wt: _____ kg
BMI: _____
Ht: _____ cm

Anesthesia Time Out
☑ NPO _____
☑ Patient ID
☑ Chart Reviewed
☑ Equip. checked
☑ Site Verified
Initials: TAE

History: HTN, GERD, ARTHRITIS.

Rx: ZANTAC, CELEXA, CARDURA, Metoprolol, Lasix, Prolosec

Review of Labs: ☑ Yes
Allergy: PCN, codeine
Upper Respir ☐ nl. _____ Describe: _____
Heart: ☑ Regular rate and rhythm Describe: _____
Lungs: ☑ Clear Describe: _____
ASA Status: ☐ 1 ☑ 2 ☐ 3 ☐ 4 ☐ 5 ☐ 6 ☐ E.
Plan: ☑ General Anesthesia ☐ Regional Anesthesia ☐ Local anesthesia infiltration with IV sedation & monitored anesthesia care

Class 1 2 3 4

Physician Signature: [signature] Time of Preop Assessment: 1200

	30	45	1300	15	30	45	1400	TOTALS
AGENTS N_2O / Air (liters)	0	1	1	1	1	0		
Des / Iso / Sev %	0	7.0	7.0	7.0	7.0	0		
O_2 L/m	8		1	1	1	8		
Propofol	200							
Fentanyl	175	125						
Rocuronium	50							
Zofran				4				
Morphine			10					
Ketorolac			10					
MONITORS ☑ NIBP	37	37	36.5	36.5	36.5	36.5		
☑ Alert ECG	NSR	NSR	NSR	NSR	NSR	NSR		
☑ Nerve St. O_2 Sat	100	100	99	98	98	99		
☑ BIS $ETCO_2$	41	34	36	37	37	42		
☑ $ETCO_2$ F_iO_2	100	44	43	43	43	90		

AIRWAY
☑ Pre O2
☑ Mask
☑ Oral Airway
☐ Nasal Airway
☐ LMA
☑ Oral ET
☐ Nasal ET UR
☑ Cuff Sec
☐ Tracheot
Size: 7.0
Blade: MACINTOSH 2
Circuit: Mapleson D
V. 594
Rate 8 / min
P-16 F-0

PRE-INDUCTION / INTRA-OPERATIVE

Pharmacy Narcotic Records

Out	TOTAL used	Waste

REMARKS: Assessed just before induction ☑
☐ Intraoperative Hypothermia (Pts started < 1 hr. < 36 C)

① Pt identified, interviewed, chart reviewed. Plan was confirmed & pt ID'd.
② IV in place.
③ Pt to OR, monitors placed. Pt preoxygenated.
③ IV induction. ETT easily placed ④ BIS ⑤ $ETCO_2$. ETT secured. Eyes taped. Pt positioned padded.
④ Spont. Vent. aware. Good head lift. Extubated. Pt to recovery. VSS. Report given.

HR-106 T-97.5 BP-105/71
SAT-957 RR-16

Fluid Totals UO 0
IN 1800 EBL <100

IV
Site: [illegible]
Gauge: 18g

PROTECTION
Eyes ☑ Tape ☐ Oint
☑ Upper Pads ☑ L ☑ R
☐ Axillary Pad
☐ FAW ☐ Upper ☐ Lower

TOURNIQUET
☐ LUE ☐ LLE
☐ RUE ☐ RLE
Setting mmHg: ____
Time min: ____

POSITION
☑ Supine ☐ Prone ☐ RLD ☐ LLD
☐ Jackknife ☐ Lithotomy ☐ Beach Chair

Post Anesthesia Evaluation

SEE EMR FOR VITAL SIGNS

Patient participated in post-anesthesia evaluation: ☑ yes ☐ no
If no, explain _____
(i.e. tracheated / unconscious)

☑ Hours stable/awake Pain score: _____
☑ No nausea/vomiting ☑ Adequate hydration
☑ No special follow-up required

Physician Signature: [signature]

PACU/ACU ARRIVAL / TRANSFER STATUS

☐ Alert ☑ Arousable ☐ Sedated
☑ Airway open SEE EMR FOR VITAL SIGNS

Anesthesia Start	to PACU	Anesthesia Stop
1214		1347

MEDICATIONS
Beta Blocker ☒ Given ☐ Not indicated
☐ Anesthetic not indicated ☐ Already on antibiotics
Vancomycin _____ g IV/IVPB @ _____ (Time)
Cefazolin 2 g IV/IVPB @ 1347 (Time)
Ketorolac _____ mg IV/IVPB @ _____ (Time)
Metoclopramide 5mg g IV/IVPB @ _____ (Time)

Renown HEALTH
ANESTHESIA RECORD

Procedure: lap Chole
Surgeon: GOMEZ MD
Anesthesiologist: FILLS MD Date: 8-5-12

M- DEMARANVILLE,DANIEL EUGE
HAR: 2446917 MR: 3305354
DOB: 10/4/1934 ADM: 8/5/2012
GOMEZ, MYRON J
8501392300

ANESTHESIA POST-OP ORDERS

*IV LR ☒ D_5LR ☐ NS ☐ D_5/0.45NS ☐ 50ml/hr ☐ 100 ml/hr ☐

*Routine monitoring per PACU protocol. Additional to include: _____

*O_2 via nasal cannula at 2-5 liters per minute or O_2 via face mask at 8-10 liters per minute until awake to maintain SA O_2 >90%

*Warming therapy if temperature <96.8°F (36°C)

*Titrate narcotics to level of pain relief and vital signs.

ADULT MEDICATIONS

*Fentanyl 12.5 mcg ☐ 25 mcg ☒ 50 mcg ☐ for immediate analgesia as needed for mild to moderate pain IV q 5 min PRN up to 250 mcg or _____ mcg and hold if respiratory rate < 8 breaths per min.

MAY SELECT ONLY ONE IV PAIN RELIEF:

Meperidine 12.5 mg ☐ 25 mg ☒ for severe pain IV q 5 minutes PRN pain up to 200 mg or _____ mg and hold if respiratory rate < 8 breaths per min.

OR

Morphine 1 mg ☐ 2 mg ☐ for severe pain IV q 5 min PRN pain up to 20 mg or _____ mg and hold for respiratory rate < _____ breaths per min.

OR

Hydromorphone 0.25 mg ☐ 0.5 mg ☐ for severe pain IV q 5 min. PRN pain up to 4 mg or _____ mg and hold for respiratory rate < _____ breaths per min.

Ketorolac 15 mg ☐ 30 mg ☐ 60 mg ☐ IM ☐ IV ☐ PRN mild to moderate pain x1

Hydrocodone w/APAP 7.5/500, 15ml po q.4 hr PRN mild pain, or 30ml po q 4 hr PRN moderate pain ☐
Oxycodone w/APAP 5/325, 5ml po q4 hr PRN moderate pain, or 10ml po q4 hr PRN severe pain ☐

Meperidine 12.5 mg ☐ 25 mg ☐ IV PRN SHIVERING. Hold if respiratory rate < _____ breaths per min. (Max 50mg)

Metoclopramide 10 mg IV x1 PRN nausea ☒
OR
Ondansetron 4 mg IV PRN nausea x1 ☒
Ondansetron 2 mg IV PRN vomiting rescue x1 ☐
Promethazine 6.25mg IV Q 10min x 4 PRN nausea ☐

Ephedrine 25 mg ☐ Vistaril 25 mg ☐ IM PRN x1 prior to discharge for persistent lightheadedness and/or nausea ☐

Metoprolol 1mg IV pm Heart Rate > 90 Q 5min Max 5mg ☐ (hold if SBP < 100)

PEDIATRIC MEDICATIONS

Acetaminophen per age or weight protocol ☐
Fentanyl 0.5 mcg/kg IV q 5 min PRN for immediate analgesia as needed for moderate pain. ☐
MAY CHOOSE ONLY ONE FOR IV PAIN RELIEF:
Demerol 0.2 mg/kg IV q 5 min PRN moderate pain, or 0.4 mg/kg IV q 5 min PRN severe pain. ☐
OR
Morphine 0.02 mg/kg IV q 5 min PRN moderate pain or 0.04 mg/kg IV q 5 min PRN severe pain. ☐
Hydrocodone w/ APAP 7.5/500 0.2 mg/kg po q 4 hours PRN pain. ☐
Ondansetron 0.15 mg/kg IV PRN nausea x1 ☐

EMERGENCY ORDERS

Follow ACLS protocol for respiratory and/or cardiac emergencies.
Give Naloxone 0.1 mg IV for respiratory rate <6/minute. May repeat q 3 min up to 0.4 mg. Notify Anesthesiologist.
Glycopyrolate 0.2 mg IV PRN for heart rate < 40 bpm. May repeat q 5 min up to 0.6 mg. Notify Anesthesiologist.
Notify Anesthesiologist at 303-2080 for any questions or problems with patient care.
Back up call 348-1900.

 Physician Signature: _____ MD Date: 8-5-12 Time: 12:14 2/26/2013 7:44 PM

3305354 DEMARANVILLE, DANIEL EUGENE 02-Aug-2012 15:28:31

DOB: 04-Oct-1934 77 Years Male Race: 9999

Dept: EKG Services
Room: FAX
Oper: DG

Dx: PRE OP

HR 53 . SINUS BRADYCARDIA
. RIGHT BUNDLE BRANCH BLOCK

ORDER:HABORNER

PR 192
QRSD 160
QT 476
QTc 447

-- AXIS --
P 88
QRS -155
T 81

Order #: 56237062
Enc ID: E501392300
Reason: preop
Standard 12
Requested By: GOMEZ, VICTOR

- ABNORMAL ECG -

Renown Health - Renown Regional Medical Center (1-01-00) Electronically signed by: Chad Bidwell M.D. 02-Aug-2012 17:33:27



Device: 4002 Speed: 25 mm/sec Lead: 10 mm/mV Chest: 10 mm/mV F 60- 0.5-40 Hz W PE090A CL P7

https://www.beau3EMR.com/PERS07/30/2013 11:33:07 H3

IMMEDIATE POST-OPERATIVE NOTE

PLEASE COMPLETE ALL ELEMENTS OF THIS *REQUIRED* FORM IMMEDIATELY FOLLOWING THE COMPLETION OF ANY INVASIVE PROCEDURE.

Postop Diagnosis: Biliary D —

Procedure: Lap O Chole

Surgeon: Gomez Assistant(s):

Anesthesiologist: Ellis Type of Anesthesia: Gen

Specimen: GB

Estimated Blood Loss: min

Findings: GB Sludge O duct

TIME:	DATE:	SIGNATURE:
10/5	/13	

Regional Medical Center
775-982-4100

South Meadows Medical Center
775-982-7000

Renown HEALTH

IMMEDIATE POST PROCEDURE NOTE

PATIENT IDENTIFICATION

M- DEMARANVILLE,DANIEL EUGE*
HAR: 2446917 MR: 3305354
DOB: 10/4/1934 ADM: 6/5/2012
GOMEZ, MYRON J
8501392330

DATE	TIME	ANESTHESIA NOTE
8/5/12	1930	Shortly after arriving in the PACU, the recovery room nurse reported that the pt became hypotensive and tachycardic with SBP's in the 80's and a pulse @ 115. Initially the pt was treated c̄ fluid bolus and supportive care. His response to fluid bolus was unsatisfactory. At that point, laboratory work was sent. Fluid bolus was continued, and a vasopressor was started to support his decreased blood pressure. I called Dr. Gomez and after discussing the situation with him, we elected to obtain a cardiology consult and admit the pt to ICU for continued work up. The pt remained tachycardic, but responded to vasopressor. I was called to the pt's bedside @ 1910 for marked hypotension and bradycardia. When I arrived at bedside, the pt was in full arrest with no detectable pulse and a heart rate on the monitors of @ 30. I immediately started CPR and called a "code". I intubated the pt after passing off the compressions to arriving staff. Adequacy of compressions was verified by feeling a femoral pulse. The pt was treated using epinephrine and atropine without restoration of rhythm or pulse. Cardiology arrived at bedside with transthoracic echocardiogram which demonstrated asystole. The code was called and the pt declared dead.
		[signature]

Renown HEALTH

Regional Medical Center
775-982-4100

South Meadows Medical Center
775-982-7000

Rehabilitation Hospital
775-982-3500

Patient Information
M- DEMARANVILLE,DANIEL EUGE
HAR: 2446817 MR: 3305354
DOB: 10/4/1934 ADM: 8/5/2012
GOMEZ, MYRON J
8501392300

RE: DEMARANVILLE, DANIEL
Page 1

PO Box 190 Duluth, GA 30096 Phone: (888) 588-4964 Fax: (770) 932-5696

09/03/2013

Informal Review

Debbie Benter
Employers

Patient Name:	DEMARANVILLE, DANIEL
Jurisdiction:	NV
Date of Injury:	01/31/1990
Claim/Policy #:	**1990204572**
Treating Provider:	NO PROVIDER CONTACT - INFORMAL REVIEW, -
PRIUM File #:	EMPLOYERS-292454
PreAuth #:	307427
PC Number:	29130828182470

File Contents:

1. Referral Form.
2. Certificate of Death dated 08/05/12.
3. Employee's Claim for Compensation/Report of Initial Treatment form dated 08/20/13.
4. Anesthesia Note dated 08/05/12.
5. Visit Notes and History and Physical Examinations dated 09/08/06, 01/25/07, 08/14/07, 01/09/08, 04/15/08, 07/16/08, 08/07/08, 11/20/08, 01/27/09, 02/20/09, 05/13/09, 06/10/09, 10/13/09, 01/26/10, 05/26/10, 08/30/10, 01/31/11, 04/25/11, 06/15/11, 06/21/11, 08/02/11, 10/26/11, 11/23/11, 12/20/11, 02/14/12, and 04/19/12 and 05/29/12 by providers at Acadia Medical Group.
6. Letter with Progress Note dated 03/30/11 by Richard Ganchan, MD of Reno Heart Physicians.
7. Stress Echocardiogram dated 03/26/11.
8. Consult dated 01/14/11 by Karen Clark, MD of Reno Heart Physicians.
9. Consultation dated 11/12/08 by David Hald, MD, Neurologist.
10. Consultation by David Mathis, MD of Nevada ENT & Hearing Associates, date unclear.
11. Flexible Cystoscopy Report dated 11/19/06 by David Hald, MD.

12. Progress Note dated 01/31/08 by Fred Fricke, MD of Nevada Gastroenterology.
13. Laboratory reports dated 10/09/09, 10/21/09, 09/30/10, 05/11/12, and 06/06/12.
14. EKG print outs.
15. Upper GI series dated 06/01/12.
16. Renal Ultrasound dated 11/11/08.
17. Ultrasound dated 08/14/07.
18. Right hand x-ray dated 01/15/07.

Discussion:
No provider contact was requested for this informal review.

The patient is a 78-year-old male with a date of industrial injury 01/31/90. Case management indicates the patient underwent gallbladder surgery and suffered cardiac arrest in the recovery room and expired on 08/05/12.

According to a urological consultation note on 11/12/08, there was mention of the patient being a retired police officer at that point and was being referred for microscopic hematuria and that he had been evaluated with a cystoscopy many years ago and that he has had microscopic blood in his urine but denied any pain, dysuria, or incontinence and that he had noted over the years some decreased force of the stream with urgency and frequency, which had responded nicely to Flomax and that there was mild erectile dysfunction and Viagra that was prescribed had worked very well. Also per 11/12/08 note, there was mention of the patient's past medical history that was noteworthy for an irregular EKG, prior appendectomy, herniorrhaphy with loss of the left testicle, and back surgery, as well as cataract surgery and on medications that included Zantac, Lexapro, and Flomax and that he had been a one-pack-a-day smoker and had been for many years. Also per 11/12/08 note, there was mention of a urinalysis that was positive for blood with 5 to 7 red blood cells per per high-power field. A nuclear matrix protein-22 test looking for abnormal cells was also positive, and this suggested a potential risk for transitional cell carcinoma of the bladder and that he had undergone an ultrasound, which was essentially normal with the exception of some simple renal cysts, and it was recommended at that point that given the presence of hematuria and his smoking that a complete work-up including urine cytology was to be submitted, along with doing a cystourcthroscopy to be scheduled next week and potentially a CT scan based on the findings.

According to a flexible cystoscopy report on 11/19/08, there was mention that after completing this evaluation the provider was pleased with the cystoscopy and a CT scan was not going to be obtained at that point but that his cytology was atypical or positive by FISH analysis then he would need a CT scan and consideration for retrograde pyelography and he would be contacted with the results once available and for follow-up he was to be seen in 6 months for a repeat urinalysis and in the interim if he should develop gross hematuria he would need to be seen sooner due to the importance of a work-up.

RE: DEMARANVILLE, DANIEL
Page 3

According to a colonoscopy report on 01/31/08, there was mention of excellent quality screening examination for colon cancer and no neoplastic tissue was identified and a repeat screening examination should be considered in 10 years per report.

The consult dated 01/14/11 by Dr. Karen Clark of Reno Heart Physicians indicates the patient was seen at the request of Concentra in consultation for abnormal EKG. The 01/14/11 note indicates on the patient's routine physical he had an ECG that showed a RBBB and RAD. It was noted the patient was told he had this previously in 2004 and he had a stress test and echocardiogram at that time and was told it was all normal except for mild LVH on the echocardiogram. The patient denied any symptoms or limitations. It was noted the patient quit smoking a few years ago. There was mention of cardiac risk factors: no diabetes mellitus, no peripheral vascular disease, no family history of coronary artery disease, no hypertension, no sedentary lifestyle and no sleep apnea. There was also mention the patient presented with complaints of abnormal cardiovascular test, starting 6 years ago. The assessment per the 01/14/11 note was abnormal electrocardiogram. The Letter with Progress Note dated 03/30/11 indicates the patient was cleared for security work without restriction with impression of right bundle branch block, no evidence of organic heart disease.

According to a clinic note on 12/20/11, there was mention of the patient having hip pain and needed a shot and no clearly detailed objective physical examination findings were listed. According to a clinic note on 02/14/12, there was mention of the patient being seen for a physical, but again no detailed objective physical examination findings were listed with mention that the patient did quit tobacco use in 2009. According to a clinic note on 04/19/12, there was mention of the patient being seen for a Kenalog injection for diffuse body aches from his polymyalgia rheumatica and physical examination included a heart that had a regular rate and rhythm without murmurs, gallops, or rubs. Lungs were clear to auscultation bilaterally. No rhonchi, wheezing, or crackles. Abdomen was soft, nontender, and nondistended and positive bowel sounds. No hepatosplenomegaly. No rebound or guarding. No tenderness. No costovertebral angle tenderness. There was diffuse swollen mildly tender joints of the shoulders bilaterally, elbows bilaterally, hands bilaterally, low back, hips, and knees, along with good range of motion of all of his extremities but that there was significant tremor and no skin rashes or lesions were noted. His diagnoses were listed as essentially and other specified forms of tremors polymyalgia rheumatica, osteoarthrosis unspecified, whether generalized or localized, and benign essential hypertension. According to a clinic note on 05/29/12, there was mention of the patient having abdominal pain, mid and epigastric that radiated around the back and up in between the shoulder blades and that this had occurred over the past 4 to 5 weeks and years ago he had peptic ulcer, along with mention that the patient had been drinking one martini per day and up to 4 to 5 martinis on the weekends and that he did acknowledge that he had an alcohol problem in the past and that he no longer smoked and quit 3 years ago. On physical examination, there was mention of the patient having cardiovascular disease, no fraction rub. No gallop. No murmur. Normal heart sounds. Pulses normal. Regular rate and rhythm. Respiratory rate, breath sounds were normal. No respiratory distress. Abdomen was obese, soft, with mild epigastric tenderness to palpation. There was no positive Murphy sign. There were no masses, and the listed diagnosis included alcohol abuse unspecified, vomiting alone, abdominal tenderness, epigastric, osteoarthrosis, unspecified whether

PAGE 4/6 * RCVD AT 9/3/2013 12:56:20 PM [Pacific Daylight Time] * SVR:HND-RFAX-PR01/7 * DNIS:7658 * CSID: * DURATION (mm-ss):02-20

PAGE 5/7 * RCVD AT 9/3/2013 6:43:23 PM [Pacific Daylight Time] * SVR:HND-RFAX-PR01/8 * DNIS:3080 * CSID:Fax Server * DURATION (mm-ss):02-37

generalized or localized, and essential hypertension benign. The treatment plan included referring the patient to gastroenterology, along with obtaining some radiologic films.

Recommendations:

1. I have been asked to determine whether there was any evidence of heart disease prior to 08/05/12 and if so, when.

   There was no indication from the available documentation/information of any specific heart disease problem occurring prior to 08/05/12 based on the available documentation/information. There was mention that as far back as 11/12/08 that the patient had a reported irregular EKG but no mention as to how this would have equated into a specific heart problem or cardiac disease issue that was occurring.

2. Was there any basis for the diagnosis of atherosclerotic heart disease as noted on the death certificate?

   It appears that the patient had some risk factors prior to the 08/05/12 surgery that could have led to the atherosclerotic heart disease as he had a long history of smoking as well as a history of alcohol abuse. While there was no mention of any specific heart problems that occurred prior to 08/05/12, these risk factors could have predisposed the patient to an atherosclerotic condition and put him at higher risk for any particular type of surgical intervention.

3. Was the myocardial infarction due to atherosclerotic heart disease or was this most likely a post-op complication?

   As mentioned in question #2, it appears that the patient had some risk factors that would have led to the atherosclerotic heart disease and would most likely not have been due to a postoperative complication of a gallbladder surgery resulting in the cardiac arrest.

This evaluation has been conducted on the basis of the medical documentation, as provided, and information provided by the treating provider(s) or authorized representative(s) with the assumption that that information is true and correct. PRIUM believes that it has made a reasonable attempt to obtain all medical records pertinent to this review and has afforded the treating provider(s) an opportunity to provide additional information in a timely manner. The opinions and conclusions are those of the reviewing physician and are derived from a synthesis and analysis of the available information and based on reasonable medical probability and generally accepted references.

If we can assist further, please let us know.

Sincerely,

RE: DEMARANVILLE, DANIEL
Page 5



Sankar Pemmaraju, D.O.
American Board of Physical Medicine and Rehabilitation
TX-K8811
CA-20A11667
SP/mm

RE: DEMARANVILLE, DANIEL
Page 1

PO Box 190 Dunwoody, GA 30026 Phone: (888) 588-4264 Fax: (770) 952-5636

09/16/2013

Informal Review

Debbie Benter
Employers

Patient Name:	DEMARANVILLE, DANIEL
Jurisdiction:	NV
Date of Injury:	01/31/1990
Claim/Policy #:	**1990204572**
Treating Provider:	NO PROVIDER CONTACT - INFORMAL REVIEW, -
PRIUM File #:	EMPLOYERS-294476
PreAuth #:	307427
PC Number:	20130828182470

File Contents:

1. Referral Form.
2. Certificate of Death dated 08/05/12.
3. Employee's Claim for Compensation/Report of Initial Treatment form dated 08/20/13.
4. Anesthesia Note dated 08/05/12.
5. Visit Notes and History and Physical Examinations dated 09/08/06, 01/25/07, 08/14/07, 01/09/08, 04/15/08, 07/16/08, 08/07/08, 11/20/08, 01/27/09, 02/20/09, 05/13/09, 06/10/09, 10/13/09, 01/26/10, 05/26/10, 08/30/10, 01/31/11, 04/25/11, 06/15/11, 06/21/11, 08/02/11, 10/26/11, 11/23/11, 12/20/11, 02/14/12, and 04/19/12 and 05/29/12 by providers at Acadia Medical Group.
6. Letter with Progress Note dated 03/30/11 by Richard Ganchan, MD of Reno Heart Physicians.
7. Stress Echocardiogram dated 03/26/11.
8. Consult dated 01/14/11 by Karen Clark, MD of Reno Heart Physicians.
9. Consultation dated 11/12/08 by David Hald, MD, Neurologist.
10. Consultation by David Mathis, MD of Nevada ENT & Hearing Associates, date unclear.
11. Flexible Cystoscopy Report dated 11/19/06 by David Hald, MD.

12. Progress Note dated 01/31/08 by Fred Fricke, MD of Nevada Gastroenterology.
13. Laboratory reports dated 10/09/09, 10/21/09, 09/30/10, 05/11/12, and 06/06/12.
14. EKG reports.
15. Upper GI series dated 06/01/12.
16. Renal Ultrasound dated 11/11/08.
17. Ultrasound dated 08/14/07.
18. Right hand x-ray dated 01/15/07.

Discussion:
No contact was requested for this review.

The patient was involved in an industrial-related injury on 01/31/90. Case management indicates the patient underwent gallbladder surgery and suffered cardiac arrest in the recovery room and expired on 08/05/12. The documentation indicates that the patient was seen for urological consultation on 11/12/08, at which time it was noted the patient was a retired police officer. He was referred for microscopic hematuria with mention he had been evaluated with a cystoscopy in the past and that he had microscopic blood in his urine. The patient denied pain, dysuria, or incontinence. There was mention that over the years there had reportedly been some decreased force of the stream with urgency and frequency, which had responded to Flomax. There was mention of mild erectile dysfunction with indication that Viagra had been prescribed and had worked very well. Also per the 11/12/08 urological consultation, past medical history was noted for an ECG showing right bundle branch block., prior appendectomy, herniorrhaphy with loss of the left testicle, back surgery, and cataract surgery. Medications had included Zantac, Lexapro, and Flomax. It was noted the patient had been a smoker for many years of one pack per day. There was also mention of a urinalysis which was positive for blood with 5 to 7 red blood cells per high-power field. A nuclear matrix protein-22 test for abnormal cells was also positive, which was noted to suggest potential risk for transitional cell carcinoma of the bladder, with mention an ultrasound had been performed which was essentially normal with the exception of some simple renal cysts. It was recommended that given the presence of hematuria and his smoking a complete work-up including urine cytology was to be completed along with a cystourethroscopy to be scheduled the following week, with potential CT scan based on the findings. According to a flexible cystoscopy report dated 11/19/08, it was noted that after this evaluation, the provider was pleased with the cystoscopy and a CT scan was not going to be obtained. It was mentioned that if his cytology was atypical, or positive by FISH analysis, then he would need a CT scan. It was noted that he was to be seen in six months for repeat urinalysis and in the interim, if he should develop gross hematuria, he would need to be seen sooner. Also according to the documentation, in a colonoscopy report dated 01/31/08, there was mention of excellent quality screening examination for colon cancer, and no neoplastic tissue was identified.

The consultation by Dr. Karen Clark of Reno Heart Physicians dated 01/14/11 indicated the patient was seen at the request of Concentra in consultation for an abnormal EKG. The 01/14/11 note indicated that upon routine physical, the patient

had an ECG that showed a RBBB and RAD. It was noted the patient was told he had this previously in 2004, with mention that he had a stress test and echocardiogram at that time and was told it was all normal except for mild LVH on the echocardiogram. The patient denied any symptoms or limitations. There was mention the patient reportedly quit smoking a few years prior. Also per the 01/14/11 report, there was mention of an absence of the following cardiac risk factors: no diabetes mellitus; no peripheral vascular disease; no family history of coronary artery disease; no hypertension; no sedentary lifestyle; and no sleep apnea. The assessment per the 01/14/11 note was abnormal electrocardiogram. The Letter with Progress Note dated 03/30/11 indicates the patient was cleared for security work without restriction, with impression of right bundle branch block, no evidence of organic heart disease. Also according to the documentation, in a note dated 12/20/11, the patient had hip pain and needed a shot. However, there were no objective physical examination findings. A note dated 02/14/12 indicated the patient was seen for a physical. There were no objective physical examination findings. There was mention the patient had ceased tobacco use in 2009. A note dated 04/19/12 indicated the patient was seen for Kenalog injection for diffuse body aches from his polymyalgia rheumatica. There was mention of physical examination noting the heart had a regular rate and rhythm without murmurs or gallops; lungs were clear to auscultation bilaterally; no rhonchi, wheezing, or crackles; abdomen soft, nontender, and non-distended; positive bowel sounds; no hepatosplenomegaly; no rebound or guarding; no tenderness; no costovertebral angle tenderness; diffuse swollen, mildly tender joints of the shoulders bilaterally, elbows bilaterally, hands bilaterally, low back, hips, and knees; good range of motion of all of his extremities; significant tremor; no skin rashes or lesions. Also per the 04/19/12 note, the diagnoses were: essentially and other specified forms of tremors polymyalgia rheumatica, osteoarthrosis unspecified whether generalized or localized, and benign essential hypertension. A note dated 05/29/12 indicated the patient reported abdominal pain, mid and epigastric, that radiated around the back and up in between the shoulder blades, and that this had occurred over the past 4 to 5 weeks. There was mention of a previous peptic ulcer; that the patient reportedly drank one martini per day and up to 4 to 5 martinis on the weekends; with mention he acknowledged an alcohol problem in the past. On physical examination per the 05/29/12 report, there was mention was mention of a normal cardiac exam: no gallop; no murmur; normal heart sounds; normal pulses; regular rate and rhythm; respiratory rate and breath sounds normal; no respiratory distress; abdomen obese, soft, with mild epigastric tenderness to palpation; no positive Murphy sign; and no masses. Also per the 05/29/12 report, the diagnoses included alcohol abuse unspecified, vomiting alone, abdominal tenderness, epigastric, osteoarthrosis unspecified whether generalized or localized, and essential hypertension benign. The treatment plan included referral to gastroenterology.

SUMMARY OF TREATMENT PLAN:

1. **Was there any evidence of heart disease prior to 08/05/12? Is so, when?**

   There was evidence of cardiovascular disease in the following forms prior to 08/05/12: Hypertension (noted on document of 05/29/12), right bundle branch block on EC (noted in 2004), and mild left ventricular hypertrophy on echocardiogram (noted in the 01/14/11 report). However, there is no evidence in the records provided of coronary artery disease, coronary heart disease, or

ischemic heart disease. There is documentation of atherosclerotic heart disease prior to 08/05/12.

2. **Was there any basis for the diagnosis of atherosclerotic heart disease as noted on the death certificate?**

   This reviewer was unable to find any documentation in the records provided that would support a diagnosis of atherosclerotic heart disease as noted on the death certificate.

3. **Was the myocardial infarction due to atherosclerotic heart disease or was this most likely a post-op complication?**

   From the records provided, there is no evidence of a myocardial infarction, particularly since cardiac enzymes were not drawn, a 12-lead ECG showing evidence of myocardial infarction is absent, and an autopsy was not performed. Thus, it appears most likely that the cardiac arrest was a post-operative complication.

This evaluation has been conducted on the basis of the medical documentation, as provided, and information provided by the treating provider(s) or authorized representative(s) with the assumption that that information is true and correct. PRIUM believes that it has made a reasonable attempt to obtain all medical records pertinent to this review and has afforded the treating provider(s) an opportunity to provide additional information in a timely manner. The opinions and conclusions are those of the reviewing physician and are derived from a synthesis and analysis of the available information and based on reasonable medical probability and generally accepted references.

If we can assist further, please let us know.

Sincerely,

Yasmine S. Ali, MD

Yasmine S.Ali, M.D., M.S.C.I, F.A.C.C., F.A.C.P.
Board Certified in Internal Medicine and Cardiovascular Disease
Diplomate, American Board of Clinical Lipidology
Board Certified in Nuclear Cardiology
TN 37911
YSI/cn

PAGE 4/4 * RCVD AT 9/16/2013 4:49:35 PM [Pacific Daylight Time] * SVR:HND-RFAX-PR01/11 * DNIS:3080 * CSID:Fax Server * DURATION (mm-ss):02-07

AFFIRMATION
Pursuant to NRS 239B.030

The undersigned does hereby affirm that the preceding **INSURER'S FIRST SUPPLEMENTAL DOCUMENTARY EVIDENCE**, filed in Nevada Department of Administration Appeal No's. 46812-LLW; 46479-LLW and 44957-LLW does not contain the social security number of any person.

TIMOTHY E. ROWE, ESQ.
Attorneys for
CITY OF RENO

1-31-14
Date

McDONALD·CARANO·WILSON
100 WEST LIBERTY STREET, 10TH FLOOR • RENO, NEVADA 89501
P.O. BOX 2670 • RENO, NEVADA 89505-2670
PHONE 775-788-2000 • FAX 775-788-2020